

Two different scenarios of advanced basal cell carcinomas during the use of vismodegib: Cases of oral administration and administration directly to the stomach

Carmen Rodríguez-Cerdeira^{1,2,*}, Victor Muñoz-Garzón³, José Luís González-Cespón¹

¹ Efficiency, Quality and Costs in Health Services Research Group (EFISALUD), Galicia Sur Health Research Institute (IIS Galicia Sur), SERGAS-UVIGO, Vigo, Spain;

² Department of Dermatology. CHUVI. Hospital do Meixoeiro and University of Vigo, Vigo, Spain;

³ Department of Radiotherapy. CHUVI. Hospital do Meixoeiro, Vigo, Spain.

Summary

No effective therapy exists for locally advanced or metastatic basal cell carcinoma (BCC). Vismodegib is a small molecule that is an inhibitor of the hedgehog pathway. An oral treatment to inactivate Smoothened would be a new therapeutic approach to treat advanced BCC. We studied two patients with advanced BCC and analysed variables, including age and sex of the patient, tumour location and size, time of evolution and nature of the tumour (primary or recurrent), type of treatment, route of administration, treatment duration, and treatment response. The most important side effects were determined. The patients received oral vismodegib (150 mg) daily. The male patient experienced difficulty in swallowing, which necessitated administration of the drug using a percutaneous endoscopic gastrostomy tube. In the first few months of treatment, both patients displayed significant improvement with almost complete disappearance of the skin lesions in one case and more than 50% in the other case. The median duration of response was 7.6 months. The side effects observed were of slight relevance; alopecia, dysgeusia, asthenia, and fatigue were easily resolved with the appropriate treatments. Vismodegib appears to be well tolerated and effective in treating advanced and metastatic BCC. No serious adverse events were reported.

Keywords: Advanced localised basal cell carcinoma (BCC), metastatic BCC, hedgehog pathway inhibitors, vismodegib, route of administration

1. Introduction

Basal cell carcinoma (BCC) has a global incidence of 70 to over 800 new cases per 100,000 persons per year. It is the most common skin tumour, accounting for 80% of the nonmelanoma skin cancer cases. Rarely, BCC progresses to locally advanced or metastatic BCC (1,2). However, some cases of BCC involve a more aggressive phenotype and the prognosis is poorer (3). Tumours with a diameter greater than 2 cm are associated with a higher risk of recurrence and metastasis. Location of lesions in the centre of the face, especially around the eyes, nose, lips, and ears, is also associated with a higher risk

of recurrence (4). Patients with recurrent lesions have a higher risk of metastasis. Mofeiform, micronodular, infiltrative and basosquamous histology subtypes pose an increased risk of recurrence and metastasis. Finally, perineural and/or perivascular involvement confers a greater risk of recurrence.

There is currently no established definition for locally advanced BCCs. It has been proposed to use this term for American Joint Committee on Cancer stage II BCCs. These tumours are > 2 cm in diameter with at least two high risk factors, which include invasion depth > 2 mm, Clark IV level, perineural invasion, facial H location and poor tumour differentiation. Other relevant added characteristics include the presence of large tumours or several tumours, presence of genodermatosis (Gorlin syndrome) and comorbidities.

All these aspects should be considered when selecting a treatment option for patients with BCC, since the

*Address correspondence to:

Dr. Carmen Rodríguez-Cerdeira, Department of Dermatology, Hospital do Meixoeiro and University of Vigo, Vigo, Spain.
E-mail: crodcer@uvigo.es

surgery can be debilitating and sometimes disfiguring. Additionally, surgery and radiotherapy are inappropriate in some cases. In these cases, non-surgical treatments may be required (5). Until the availability of approved systemic therapy there has been no effective treatment for this type of patients.

Vismodegib is the first and, so far, only Food and Drug Administration approved oral therapy for advanced and metastatic BCC (6,7). Vismodegib is an orally administered compound. It is a selective first-in-class hedgehog pathway inhibitor. The Sonic Hedgehog (SHH) pathway plays a key role in the regulation of cell differentiation and organ formation during embryonic development. In adults the SHH pathway remains inactive in most tissues (8,9). Vismodegib specifically binds and inactivates the seven transmembrane helical fold Smoothed receptor (SMO), which slows the activation of the family of transcription factors of the glioma-associated oncogene (GLI) and suppresses proliferation and tumour growth (10).

In this manuscript, we review the results of vismodegib treatment of BCC in two patients. One patient had metastatic BCC and the other had advanced localised BCC. We focused on the mechanism of action, clinical efficacy, and safety of vismodegib.

2. Case report

2.1. Case 1

A 76-year-old woman presented with a large (8 × 14 cm) ulcerated lesion in the retro-auricular zone, with an extension to the right parieto-occipital region (Figure 1).

The lesion had progressed over a period of 7 years with invasion of the bones and cerebellum. The patient was not a candidate for surgery because the tumour was inoperable. Radiotherapy was contraindicated due to the extension of the tumour, which included invasion of the central nervous system. Skin findings showed BCC with keratotic differentiation. Biopsy of the right parieto-occipital bone revealed BCC infiltration of bone tissue and acute osteomyelitis with gram-positive

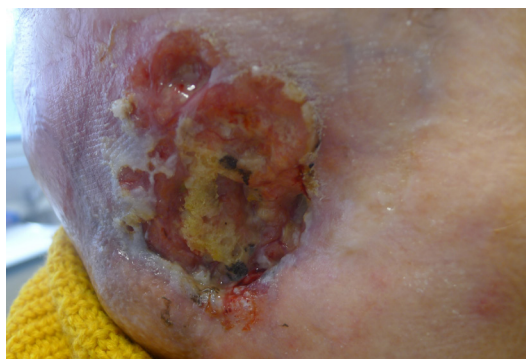


Figure 1. Macroscopic findings at the beginning of treatment with vismodegib. Representative image of the tumour with a size of 10.5 × 13 cm. No auricular palate is observed due to previous surgeries.

bacteria. Immunohistochemistry analysis confirmed the absence of CD56 and Cd117 (C-Kitt). The patient had no previous family history of skin cancer, and did not present with other suspicious lesions during clinical examination. Total body computed tomography scans and positron emission tomography imaging revealed the involvement of the underlying bones and cerebellum, with no evidence of distant spread (Figure 2).

The findings from magnetic resonance imaging suggested extensive tumour involvement in the subcutaneous tissue from the right temporal area to the deep right suboccipital area and neck, with the involvement of the skull base, right portion of C1, and extension to the right epidural area at the C1 level of the spinal canal. There was no evidence of marrow involvement. Complete staging including the thorax, abdomen and pelvis did not reveal BCC metastasis. The patient was started on vismodegib with a standard oral dose of 150 mg/day. No other medications were used. The patient was evaluated for the effect of treatment 4, 16 and 36 weeks after the initiation of treatment. Appreciable improves were evident and included decreased tumour size and signs of healing in the periphery (Figure 3).

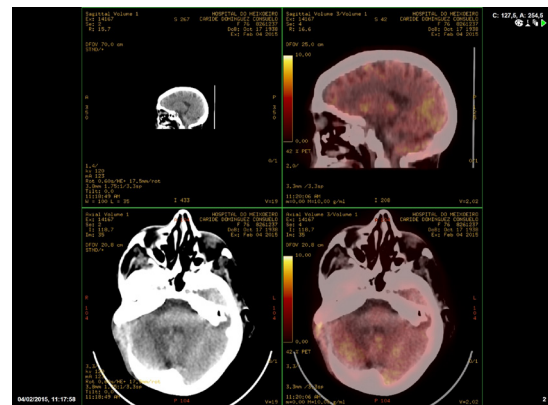


Figure 2. Patient's total-body computed tomography and positron emission tomography imaging at the beginning of treatment. Right skull base shows intensive pathological hypercapitation associated with soft tissue involvement extending into the right paravertebral region of C2.

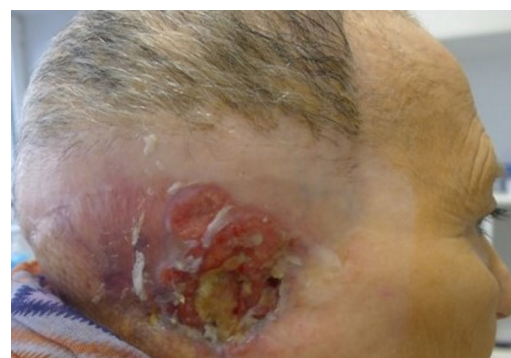

Figure 3. Macroscopic findings after four months of treatment. Marked reduction of the tumour size by 50% and abundant tumour areas of tissue repair.

Table 1. Demographic and clinical characteristics of the patients and follow-up data

BCC type	MBCC (Case 1)	BCC-la (Case 2)
Age, years	76	80
Sex		
Male		1
Female	1	
Contraindications to surgery or radiation therapy	1	1
Inoperable tumour	1	
Surgery inappropriate	1	1
Multiple recurrences	1	1
Substantial morbidity or deformity anticipated	1	
Radiation therapy previously administered	1	1
Treatment	Vismodegib 150 mg/oral/24 h	Vismodegib 150 mg dissolved in 50 cc of hot water per gastrostomy tube/24 h
Radiation therapy inappropriate or contraindicated	1	1
Response Evaluation Criteria (RECIST 1.1)	Decrease of more than 50% of the sum of the diameter of the target lesion	Virtually complete disappearance of target skin lesions (90%)
Clinical benefit rate (partial or complete response at any time (before or after progression)) + stable disease for 4 or more weeks	1	1
Average time to maximum tumour reduction	4 months	3.5 months
Deaths	1	1
Aspiration pneumonia		1
Multi-organ failure	1	

mBCC: Metastatic basal-cell carcinoma. laBCC: localised advanced basal-cell carcinoma.

Table 2. Adverse events

Symptomatology	Patients	Grade	Treatment	Response to treatment
Alopecia	1	1	Minoxidil 5% twice daily	Partial response
Dysgeusia	1	2	Zinc supplements, continuous nutritional support	Regression of symptoms
Asthenia/fatigue	2	1	Physical activity, including yoga, Fluoxetine 20 mg/oral/24 h	Regression of symptoms

The side effects were minimal and included constipation and fatigue. They were manageable. The patient ultimately died of multiple organ failure but in not relationship with the vimodegib treatment (Tables 1 and 2).

2.2. Case 2

A 76-year-old man was originally referred to the neurology department for recurrent apnoea and asymmetric parkinsonian onset. He was then referred to our clinic for recurrence of lesions on the scalp and face. He presented with multiple BCC tumours in the left parietal and occipital region, which met the criteria for BCC that was inoperable with multiple recurrences. This is associated with important morbidities and deformities that can include the forehead, temple and external auditory canal. Clinical history-taking revealed more than 20 recurrences of BCC. During the previous 5 years he had been operated on several times, with grafts applied to virtually the entire scalp and 40% of the facial area (Figure 4).

The graft tissue had been obtained from the abdomen, which had produced scarring. Multiple biopsies had been performed. The results were consistent with BCC. Prior magnetic resonance imaging had revealed infiltration of the bone marrow of the left parietal bone in the parasagittal region and diffuse corticosubcortical atrophy

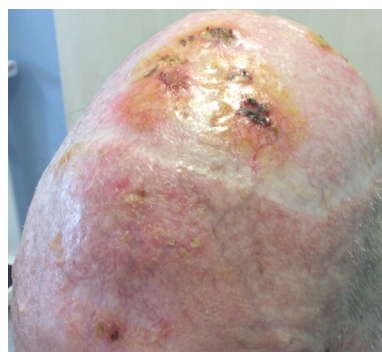

Figure 4. Macroscopic findings before treatment with vismodegib. Crusted ulcerative lesions are observed on the scalp and grafts, after multiple previous surgeries.

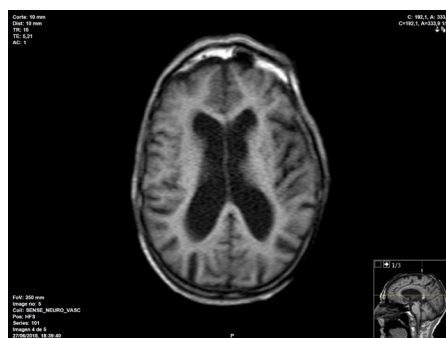

Figure 5. Magnetic resonance image of the tumour. Early phase of the disease showing the important invasion of the tumour towards the left parietal bone.

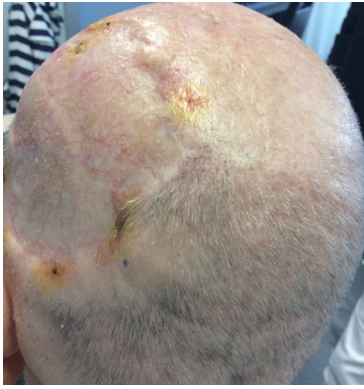


Figure 6. Macroscopic findings. Disappearance of skin lesions after 6 months of treatment with vismodegib.

was observed (Figure 5).

Following admission, swallowing was affected by a concentric stenosis at the level of the pharyngoesophageal junction. Therefore, percutaneous endoscopic gastrostomy (PEG) was done and a 14F retention balloon catheter was installed. There were no immediate or longer-term complications. The patient was treated solely with oral vismodegib 150 mg initially. The same dose was subsequently diluted in 50 cc of warm water and administered *via* the catheter. The treatment was well tolerated with no side effects associated with vismodegib or the other drugs that continued to be used. The patient was evaluated at 4, 16 and 36 weeks after the initiation of treatment. Nearly total remission of the skin lesions was observed (Figure 6).

Ultimately, the patient died. Death was not related to the vismodegib, but rather to aspiration pneumonia (Tables 1 and 2).

3. Discussion

BCC is usually treated by surgery alone or in combination with radiotherapy. However, treatment options are limited for the minority of patients who present with locally advanced or metastatic BCC. Overall survival estimates for patients with metastatic disease are poor, ranging from 8 months to 3.6 years. In one study, the incidence of advanced or complicated BCCs in a tertiary referral centre was 6.6% (640 of 9,652) moderate cases and 0.6% (58 of 9,652) severe cases (11).

Vismodegib is a targeted inhibitor of SMO, which decreases the activity of the hedgehog-signalling pathway and subsequently reduces basal cell proliferation. A durable reduction in the size of unresectable, metastatic, and potentially disfiguring or invasive BCC has been a direct clinical benefit of treatment with vismodegib (12).

A number of clinical trials have supported the approved use of vismodegib for BCC. In one trial 63 patients with locally advanced BCC and 33 patients with metastatic BCC, the rates of the response of the patients

Table 3. Summary of efficacy findings of the largest clinical trials investigating vismodegib in laBCC and mBCC

No. of patients enrolled (laBCC)	No. of patients enrolled (mBCC)	Study type	Treatment	Mean treatment duration (months)	Response rate (*laBCC)	Response rate (*mBCC)	Reference
62	57	Open-label, multicenter study	Vismodegib 150 mg orally	5.5	46.4%	30.8%	Chang <i>et al.</i> 2014 (19)
113 (included patients with Gorlin syndrome)		Phase II, randomized, controlled, double-blind trial	Vismodegib 150 mg orally	18.5	**58.4%		Dreno <i>et al.</i> 2015 (17)
71	33	Phase II, two-cohort, multicenter study	Vismodegib 150 mg orally	39	60.3%	48.5%	Sekulic <i>et al.</i> 2017 (15)
1,119	96	Phase II, single-arm, multicenter, open-label study	Vismodegib 150 mg orally	8.6	***68.5%	***36.9%	Basset-Seguin <i>et al.</i> 2017 (16)
55	-	Phase II trial multicenter, open-label study	Vismodegib 150 mg orally		80%	-	Mortier <i>et al.</i> 2018 (18)
-	2	Clinical practice	Vismodegib 150 orally + concurrent radiotherapy (66 Gy in 33 fractions for case 1 and (12.5 and 22.3 Gy) for case 2	10.5	-	Stable disease apparent on imaging	Pollom <i>et al.</i> 2015 (20)
-	4	Clinical practice	150 mg orally+ 20% 5-aminovalulinic acid in 1-3 sessions	1	-	100%	Rizzo <i>et al.</i> 2017 (21)
1	1	Clinical practice	Vismodegib 150 mg orally and through a PEG****	7.5	50%	100% and stable disease apparent on imaging	(Current cases)

* laBCC: locally advanced basal cell carcinoma; mBCC: metastatic basal cell carcinoma. ** 54% for group A, 62.8% for group B. *** laBCC (total 34%, partial in 33%, and stable in 26%); mBCC (2 total, 9 partial and 10% stable). **** PEG: Percutaneous endoscopic gastrostomy.

were 43% and 30% respectively. The median duration of response was 7.6 months in both cohorts. Adverse events occurred in more than 30% of the patients (13). In the pivotal nonrandomised ERIVANCE study (NCT00833417) published in 2015 by the same authors, 104 patients (33 metastatic BCC, 71 locally advanced BCC) were enrolled. During a 12-month period the response rate increased with time, with overall response rates of 30.3% for the metastatic BCC patients and 47% for the locally advanced BCC patients. The median duration of response in the latter patients was increased 2.1 months compared to a study published in 2012 (14). The final results of ERIVANCE were published in 2017 with a cut-off at 39 months after completion of accrual (15). The response rate was 60.3% for locally advanced BCC patients and 48.5% for the metastatic BCC patients (Table 3).

The open-label STEVIE study [NCT01367665 (15)] enrolled a total of 1,232 patients. These included 499 patients (468 with locally advanced BCC and 31 with metastatic BCC) who received vismodegib and were followed-up for a minimum of 12 months. The primary objective was drug safety. For the patients with locally advanced BCC, the rate of complete response and partial response was 34% and 33%, respectively, and a stable response was observed in 26% of patients. For the patients with metastatic BCC, the respective response rates were 2%, 9% and 10% respectively (16).

The randomised, double-blind, phase II MIKIE study NCT01815840 (17) included patients with multiple BCCs, including those with basal cell nevus (Gorlin) syndrome, who required extended treatment. A total of 229 patients were randomised to two treatments (116 in treatment group A and 113 in treatment group B). Both groups received intermittent treatment with vismodegib 150 mg daily and placebo. The decrease in the mean number of tumours at 73 weeks of follow-up was 62.7% in group A and 54.0% in group B (17).

The objective of the open-label, phase II VISMONEO study NCT02667574 (18) was to evaluate the reduction of the size of locally advanced BCC tumours located on the face after neoadjuvant treatment involving vismodegib, to explore the strategy as a means of reducing the need for surgery. The study enrolled 55 patients who were contraindicated for surgery; four were inoperable, 15 had a risk of major functional damage and 36 had a risk of minor functional risk or major aesthetic risk. Eighty percent of the patients displayed a treatment response and the severity of the surgery was reduced. Chang *et al.* (19) described 119 patients treated with vismodegib for over 5 months. Response to treatment was observed in 46.4% of patients with locally advanced BCC and 30.8% of patients with metastatic BCC. The most important side effects were muscle spasms (70.6%), dysgeusia (70.6%), alopecia (58.0) and diarrhoea (25.2%).

Concerning the integration of vismodegib with

existing therapies, prior publications have documented similar experiences regarding vismodegib in combination with radiotherapy. The data indicate the excellent response and good tolerance of patients. Pollom *et al.* (20) reported on two patients with metastatic BCC treated with vismodegib 150 mg concurrent with radiotherapy. At a mean follow-up of 10.5 months, imaging analyses revealed apparent stable disease in both patients, with reduced facial weakness and absence of pain. Rizzo *et al.* (21) obtained excellent results with photodynamic therapy and vismodegib in patients with metastatic BCC, involving three applications of 20% 5-aminolevulinic acid. The photodynamic therapy was applied 7 ± 4 days after starting vismodegib and was repeated at 45 ± 5 days and 90 ± 10 after treatment began. The combination of photodynamic therapy and vismodegib was judged to be a potential safe and effective therapy for the treatment of multiple BCCs.

The present results of our patients corresponded to the usual clinical practice, in which the long-term use of SHH inhibitors are not sustainable, in some cases due to the presence of comorbidities, especially in very elderly patients. Our response rates were similar or better than those reported in the previous tests (14-17). It is noteworthy that we did not have to suspend the treatment in any case, irrespective of whether vismodegib was administered orally or *via* catheter. Table 3 summarises studies that involved the treatment of locally advanced or metastatic BCC and metastatic, including the present patients.

The available data, including the present data, indicate that vismodegib is a safe and effective drug for the treatment of locally advanced and metastatic BCC when surgery and radiotherapy are not options. In our patients, the percentage of response to treatment in the cutaneous target lesions varied between 50% and 90%. Adverse effects should be taken into account since they can be frequent. In our patients the adverse events were manageable and resolved without major problem and without having to interrupt the treatment. To our knowledge, this is the first case study to date of treatment with vismodegib in advanced BCC involving administration orally or directly to the stomach *via* a catheter. No loss of efficacy or added adverse side effects were evident.

Our contribution to literature demonstrates the importance of vismodegib treatment in advanced and metastatic BCC as well as a new administration route for patients with difficulties in swallowing.

Availability of data and materials The datasets used and/or analyzed during the present study are available from the corresponding author on reasonable request.

Ethics approval and consent to participate The authors declare that the procedures followed were in accordance

with the ethical standards of the responsible committee on human experimentation (institutional and national) and with the Helsinki Declaration of 1975, as revised in 2000.

Patient consent for publication Written informed consent was obtained from the patient regarding the publication of the case details and any accompanying images.

References

- Alter M, Hillen U, Leiter U, Sachse M, Gutzmer R. Current diagnosis and treatment of basal cell carcinoma. *J Dtsch Dermatol Ges.* 2015; 13:863-874.
- Goldenberg G, Karagiannis T, Palmer JB, Lotya J, O'Neill C, Kisa R, Herrera V, Siegel DM. Incidence and prevalence of basal cell carcinoma (BCC) and locally advanced BCC (LABCC) in a large commercially insured population in the United States: A retrospective cohort study. *J Am Acad Dermatol.* 2016; 75:957-966.
- Berking C, Hauschild A, Kölbl O, Mast G, Gutzmer R. Basal cell carcinoma treatments for the commonest skin cancer. *Dtsch Arztebl Int.* 2014; 111:389-295.
- Lear JT, Corner C, Dziewulski P, Fife K, Ross GL, Varma S, Harwood CA. Challenges and new horizons in the management of advanced basal cell carcinoma: A UK perspective. *Br J Cancer.* 2014; 111:1476-1481.
- Walling HW, Fosko SW, Geraminejad PA, Whitaker DC, Arpey CJ. Aggressive basal cell carcinoma: Presentation, pathogenesis, and management. *Cancer Metastasis Rev.* 2004; 23:389-402.
- Cirrone F, Harris CS. Vismodegib and the hedgehog pathway: A new treatment for basal cell carcinoma. *Clin Ther.* 2012; 34:2039-2050.
- Vornicova O, Bar-Sela G. Rapid response to vismodegib in a patient with advanced basal cell carcinoma. *JAAD Case Rep.* 2015; 1:267-268.
- Girardi D, Barrichello A, Fernandes G, Pereira A. Targeting the Hedgehog pathway in cancer: Current evidence and future perspectives. *Cells.* 2019; 8:E153.
- Lyons TG, O'Kane GM, Kelly CM. Efficacy and safety of vismodegib: A new therapeutic agent in the treatment of basal cell carcinoma. *Expert Opin Drug Saf.* 2014; 138:1125-1132.
- Yan BY, Hibler BP, Menge T, Dunn L, Ho AL, Rossi AM. Sonic Hedgehog pathway inhibitors: From clinical trials to clinical practice. *Br J Dermatol.* 2019. doi: 10.1111/bjd.17692.
- Dreier J, Cheng PF, Bogdan Alleman I, Hafner J, Tschopp A, Goldinger SM, Levesque MP, Dummer R. Basal cell carcinomas in a tertiary referral centre: A systematic analysis. *Br J Dermatol.* 2014; 71:1066-1072.
- Meiss F, Andrlová H, Zeiser R. Vismodegib. *Recent Results Cancer Res.* 2018; 211:125-139.
- Sekulic A, Migden MR, Oro A E, *et al.* Efficacy and safety of vismodegib in advanced basal-cell carcinoma. *N Engl J Med.* 2012; 366:2171-2179.
- Sekulic A, Migden MR, Lewis K, *et al.* Pivotal ERIVANCE basal cell carcinoma (BCC) study: 12-month update of efficacy and safety of vismodegib in advanced BCC. *J Am Acad Dermatol.* 2015; 72:1021-1026.
- Sekulic A, Migden MR, Basset-Seguín N, *et al.* Long-term safety and efficacy of vismodegib in patients with advanced basal cell carcinoma: Final update of the pivotal ERIVANCE BCC study. *BMC Cancer.* 2017; 17:332.
- Basset-Seguín N, Hauschild A, Grob JJ, *et al.* Vismodegib in patients with advanced basal cell carcinoma (STEVIE): A pre-planned interim analysis of an international, open-label trial. *Lancet Oncol.* 2015; 16:729-736.
- Dréno B, Kunstfeld R, Hauschild A, Fosko S, Zloty D, Labeille B, Grob JJ, Puig S, Gilberg F, Bergström D, Page DR, Rogers G, Schadendorf D. Two intermittent vismodegib dosing regimens in patients with multiple basal-cell carcinomas (MIKIE): A randomised, regimen-controlled, double-blind, phase 2 trial. *Lancet Oncol.* 2017; 18:404-412.
- Mortier L, Bertrand N, Basset-Seguín N, Saiag P, Dupuy A, Dalac-Rat S, Bernard Guillot, Templier C, Desmedt E, Duhamel A, Guerreschi P. Vismodegib in neoadjuvant treatment of locally advanced basal cell carcinoma: First results of a multicenter, open-label, phase 2 trial (VISMONEO study). *J Clin Oncol.* 2018; 36 (15 Suppl): 9509-9509.
- Chang AL, Solomon JA, Hainsworth JD, Goldberg L, McKenna E, Day BM, Chen DM, Weiss GJ. Expanded access study of patients with advanced basal cell carcinoma treated with the Hedgehog pathway inhibitor, vismodegib. *J Am Acad Dermatol.* 2014; 70:60-69.
- Pollom EL, Bui TT, Chang ALS, Colevas AD, Hara WY. Concurrent vismodegib and radiotherapy for recurrent, advanced basal cell carcinoma. *JAMA Dermatol.* 2015; 151:998-1001.
- Rizzo JM, Segal RJ, Zeitouni NC. Combination vismodegib and photodynamic therapy for multiple basal cell carcinomas. *Photodiagnosis Photodyn Ther.* 2018; 21:58-62.

(Received March 9, 2019; Revised April 17, 2019; Accepted April 21, 2019)