

Visual improvement in a patient with paracentral acute middle maculopathy treated with prostaglandin E1

Robert Davis Steigerwalt Jr.^{1,*}, Marcella Nebbioso²

¹ Via A. Brofferio 6, Rome, Italy;

² Department of Sense Organs, La Sapienza University of Rome, Rome, Italy.

SUMMARY The authors present the use of prostaglandin E1 (PGE1) for the treatment of an acute paracentral acute middle maculopathy (PAMM). A 78-year-old white female was seen with a sudden loss of vision in her left eye (OS) to 20/200 noted upon awakening. The right eye (OD) saw 20/20. A complete eye exam was done and an ocular coherent tomography revealed retinal thickening and a whitening of the inner nuclear layer in the area of the macula OS. A diagnosis of PAMM in the OS was made. Treatment was immediately started with 70 µg of PGE1 administered over 1.5 hours in the form of a skin cream. A volume of 3.5 cc of skin cream was applied in divided doses to the inner surface of the forearm, rubbed into the skin and allowed to dry. The same 70 µg of PGE1 in 3.5 cc of skin cream was repeated once the next morning. The patient began to see better the second day of treatment with a final visual acuity of 20/20. The OD was unchanged. After 14 months she was stable with no further treatment. PAMM is an ischemic process of the inner retina. PGE1, a potent vasodilator of the microcirculation, when given immediately seemed to be useful in restoring vision in this form of retinal ischemia. Treatment was immediately started with PGE1 in the form of a skin cream with visual improvement. The authors normally use PGE1 intravenously for acute ocular ischemia and would have preferred that here. Intravenous PGE1 was not available and was substituted with the skin cream of PGE1 that worked well for the patient.

Keywords paracentral acute middle maculopathy, acute retinal ischemia, prostaglandin E1

1. Introduction

Paracentral acute middle maculopathy (PAMM) is the spectral domain-optical coherent tomography (SD-OCT) finding of a hyperreflective band involving the inner nuclear layer (INL) resulting from ischemia at the level of the deep vascular complex which is made up of the intermediate and deep retinal capillary plexus of the retina (1). Perivenular retinal whitening can be seen in the macula. The final visual acuity can vary and there is no known therapy for the ischemic lesion in the retina.

Prostaglandin E1 (PGE1), a powerful vasodilator of the microcirculation, improves ocular blood flow in the presence of peripheral vascular disease and diabetes (2). In cases of acuity ocular ischemia, intravenous (*i.v.*) PGE1 given 1 µg/kg leads to visual improvement. In nonarteritic anterior ischemic optic neuropathy (3) and nonarteritic posterior ischemic optic neuropathy (4,5), *i.v.* PGE1 with steroids was shown to improve the visual acuity as well as the ocular and retrobulbar blood flow. An acute branch retinal arterial occlusion has also been successfully treated (6). In this case report PGE1

was not immediately available for *i.v.* administration but only in the form of a skin cream. Since treatment could not be delayed, PGE1 was given in the form of a skin cream in the same dosage that would be used *i.v.* This appeared to be successful which will be explained in the paper.

2. Case Report

A 78-year-old white female was seen in the morning of December 12, 2018 with a sudden loss of vision in her left eye (OS) noted upon awakening. She was under treatment for ocular hypertension and anemia. She was 20/20 in her right eye (OD) and 20/200 in the OS measured using the Early Treatment Diabetic Retinopathy Study letter scoring. There was a white inferior parafoveal semicircular lesion 1 disc diameter in width OS. SD-OCT revealed retinal thickening and a hyperreflective band in the INL extending into the inner retina (Figure 1 panel A). A diagnosis of PAMM in the OS was made. After explaining the urgency of the situation, written informed consent was obtained for

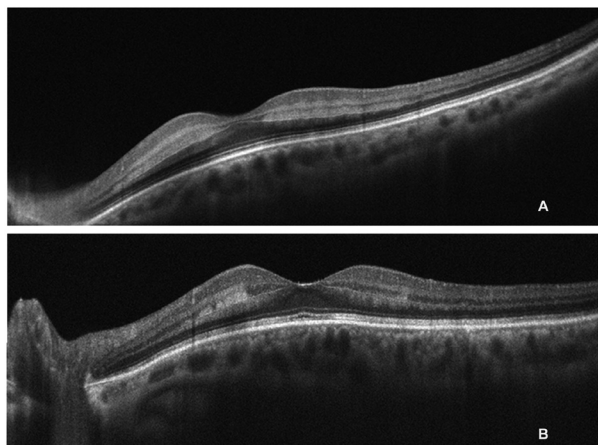


Figure 1. Spectral domain-ocular coherent tomography (SD-OCT) of the left eye of the patient. (panel A) before treatment revealed retinal thickening and a whitening of the inner nuclear layer (INL); (panel B) 9 days after treatment showed decreased retinal thickening with a reduction of the white lesion of the INL.

treatment and for the collection of clinical information for archival and research purposes. The patient weighed 70 kg. The normal dosage of *i.v.* PGE1 to treat acute ocular ischemia is 1 µg/kg or 70 µg in this case. IV PGE1 was not available so treatment was immediately started with 70 µg of PGE1 administered over 1.5 hours in the form of a skin cream. A quantity of 3.5 cc of skin cream was applied in divided doses to the inner surface of the forearm, rubbed into the skin and allowed to dry. The same 70 µg of PGE1 in 3.5 cc of skin cream was repeated once the next morning. The patient noted visual improvement during the second day of treatment but was seen 9 days later on December 21, 2018. The acuity of the OD was stable and in the OS improved to 20/20. At that time the SD-OCT showed decreased retinal thickening with a reduction of the white lesion of the INL. (Figure 1 panel B). No further treatment with PGE1 was done. She was last seen on February 12, 2020 with 20/20 OS.

3. Discussion

The patient was seen with an acute ischemic episode of PAMM in the OS. Treatment was immediately started with PGE1 in the form of a skin cream with visual improvement. The authors normally use *i.v.* PGE1 for acute ocular ischemia (3-6) and would have preferred that here. With *i.v.* treatment in acute ocular ischemia, the authors are more certain to achieve clinically significant therapeutic levels. IV PGE1 was not available and was

substituted with a topical skin cream of PGE1 which worked well for the patient. The authors however still recommend *i.v.* treatment in this form of acute ocular ischemia.

It is also important to note that treatment was started immediately and that this case of PAMM was treated only once over 2 days. Good visual acuity was maintained for 14 months without further treatments.

Conflict of Interest:

The author, RDS, has a financial interest in the prostaglandin E1 skin cream mentioned in the case report. MN has no financial interest.

References

1. Bakhom MF, Freund KB, Dolz-Marco R, Leong BCS, Bauml CR, Duker JS, Sarraf D. Paracentral acute middle maculopathy and the ischemic cascade associated with retinal vascular occlusion. *Am J Ophthalmol.* 2018; 195:143-153.
2. Steigerwalt RD Jr, Belcaro GV, Christopoulos V, Incandela L, Cesarone MR, De Sanctis MT. Ocular and orbital blood flow velocity in patients with peripheral vascular disease and diabetes treated with intravenous prostaglandin E1. *J Ocul Pharmacol Ther.* 2001; 17:529-535.
3. Steigerwalt RD Jr, Cesarone MR, Belcaro G, Pascarella A, De Angelis M, Bacci S. Nonarteritic anterior ischemic optic neuropathy treated with intravenous prostaglandin E1 and steroids. *Int J Angiol.* 2008; 17:193-196.
4. Steigerwalt RD Jr, Cesarone MR, Belcaro G, De Angelis M, Pascarella A, Nebbioso M. Non-arteritic posterior ischemic optic neuropathy treated with intravenous prostaglandin E1 and oral corticosteroids. *Neuroophthalmology.* 2011; 35:81-84.
5. Steigerwalt RD Jr, Pascarella A, De Angelis M, Grimaldi G, Nebbioso M. Three episodes of non-arteritic posterior ischemic optic neuropathy in the same patient treated with intravenous prostaglandin E1. *Drug Discov Ther.* 2016; 10:177-180.
6. Steigerwalt RD Jr, Belcaro G, Cesarone MR, De Angelis M, Florio FR, Gattegna R, Pascarella A. Branch retinal arterial occlusion treated with intravenous prostaglandin E1 and steroids. *Retin Cases Brief Rep.* 2011; 5:355-357.

Received March 17, 2020; Revised April 21, 2020; Accepted April 27, 2020.

*Address correspondence to:

Robert D. Steigerwalt Jr., Via A. Brofferio 6, Rome 00195, Italy.

E-mail: r.steigerwalt@libero.it