

Lymphoma versus thymoma: A diagnostic challenge

Sagnik Biswas¹, Sujay Halkur Shankar¹, Animesh Ray^{1,*}, Prashant Ramteke²

¹Department of Medicine, All India Institute of Medical Sciences, New Delhi, India;

²Department of Pathology, All India Institute of Medical Sciences, New Delhi, India.

SUMMARY T-cell acute lymphoblastic lymphoma is a common hematological malignancy of childhood. It can involve the bone marrow, blood, or tissues like the thymus, lymph nodes as well as extra-nodal sites. Two aspects of the disease make early diagnosis critical - the clinically aggressive nature of the neoplasm, and availability of effective chemotherapy against the disease. Diagnosis is largely based on clinical suspicion and confirmation by histopathological examination of the affected tissue. However, biopsy results may not always be helpful in establishing the diagnosis. We describe the case of an 18-year old patient presenting with fever and an anterior mediastinal mass suspected to have a T-cell lymphoma where an initial biopsy from the mass had features of a thymoma. The patient was kept in close follow up for 2 months when there was a recurrence of symptoms and a repeat bone marrow evaluation revealed a T-cell lymphoma.

Keywords lymphoma, thymoma, fine-needle biopsy, mediastinal neoplasms

1. Introduction

T-cell acute lymphoblastic lymphoma (ALL) is a common hematological malignancy of childhood comprising of almost 15% of all acute childhood leukemias (1). The disease commonly affects lymph nodes, thymus or the bone marrow, presenting variably as an anterior mediastinal mass, pancytopenia or generalized lymphadenopathy. The diagnosis is usually straightforward, based on clinical features supported by histopathological evidence from the affected tissue. However, it is often thrown into doubt when there is a disagreement between histopathological findings and clinical features. We describe the case of an 18-year-old male suspected to have T-cell lymphoma clinically, with biopsy findings indicative of a lymphocyte rich thymoma where the patient was kept in close follow up with later biopsies confirming T-cell lymphoma.

2. Case report

An 18-year-old male presented with complaints of dry cough of six months duration with progressive shortness of breath, significant weight loss, and intermittent high-grade fevers for one month. Physical examination revealed left supraclavicular and axillary lymphadenopathy. Chest auscultation revealed reduced breath sounds over the left lower lung zones. Mediastinal widening with left pleural effusion was noted on chest radiogram. A subsequent contrast enhanced

computerized tomography scan of the thorax evidenced a large homogeneously enhancing structure encased by the mediastinal vasculature along with left pleural effusion and minimal pericardial effusion (Figure 1). The initial hemogram and reticulocyte count was within normal limits with the metabolic panel revealing hyperuricemia (12.8 mg/dL) and an elevated lactate dehydrogenase level of 1,212 U/L (Normal = 420 U/L). A provisional diagnosis of lymphoma was made and the patient was evaluated further. Thoracentesis yielded exudative pleural fluid with no atypical cells. Fine needle aspiration of the supraclavicular lymph nodes was unrevealing. A biopsy of the mass was not feasible due to close proximity of mediastinal vessels. Hence, it was sampled by means of an ultrasound guided fine needle aspiration (FNA).

During the hospital course, the patient developed worsening respiratory distress and stridor due to increasing tracheal compression by the mediastinal mass. With the clinical suspicion of lymphoma, he was started on dexamethasone as a life-saving intervention despite a lack of histopathological evidence. His symptoms dramatically improved on steroids with diminution of lymphadenopathy, further supporting our suspicion of lymphoma.

The aspirate, however, revealed a focal meshwork of epithelioid cells staining positive for pancytokeratin with a predominant lymphoid background immunopositive for CD3 and terminal deoxynucleotidyl transferase (TdT) (Figure 2) consistent with the diagnosis of B1 subtype of

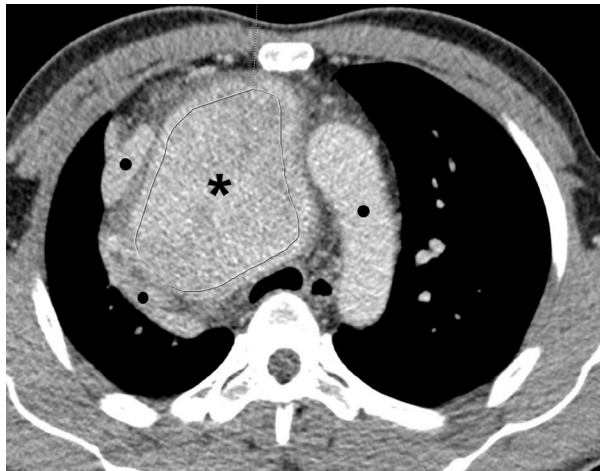


Figure 1. Contrast enhanced computerized tomography image of the thorax showing enhancing mediastinal mass (Asterix) encased by the mediastinal vasculature (Black ●).

thymoma as per the WHO classification. As this report was not compatible with our provisional diagnosis and clinical response to steroids, a bone marrow biopsy was done to look for evidence of occult hematologic malignancy. The bone marrow biopsy at this time was non-contributory. In light of clinical improvement but lack of evidence to support our diagnosis, it was decided to keep the patient on close follow up after discharge for further evidence of the natural progression of the disease. He was asymptomatic for a month after which he developed intermittent fevers and pancytopenia. The diagnosis was reached at this time by a repeat bone marrow biopsy which now revealed a diffuse infiltration by sheets of blasts immunopositive for Tdt consistent with acute lymphoblastic lymphoma. He is now on regular follow up at the cancer clinic having gone into remission after multiple cycles of chemotherapy.

3. Discussion

This case illustrates the dilemma of differentiating a T-cell ALL from a lymphocyte-rich thymoma. It also emphasizes on the importance of clinical acumen during decision making in the absence of diagnostic evidence. In children, lymphoblastic tumors are the most common cause of an anterior mediastinal mass constituting nearly 45% of the cases. Non-Hodgkin's lymphoma presenting solely as a mediastinal mass is very rare with an incidence of 5%. Thymomas, on the other hand, are uncommon in children and young adults showing increasing incidence with age (2).

Diagnosis of an anterior mediastinal mass includes a concurrent consideration of the patient's clinical presentation, radiological and histopathologic evidence. Considering symptomatology, a short history of days to weeks with the presence of 'B' symptoms, significant lymphadenopathy and pleural effusion in males

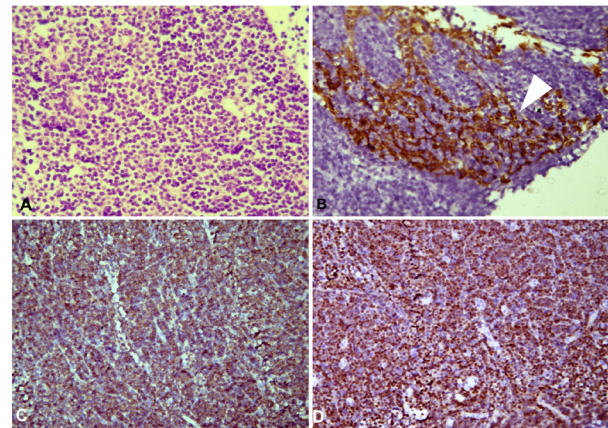


Figure 2. Histopathological and immunohistochemistry images from the aspirate of the anterior mediastinal mass. (A). Small to intermediate sized lymphoid cells (40× magnification). (B). Focal meshwork of pan-cytokeratin positive epithelial cells (White arrowhead) (20× magnification). (C). Immunohistochemistry showing background cells staining positive for CD3 (20× magnification). (D). Immunohistochemistry showing background cells staining positive for Tdt (20× magnification).

between 10 and 40 years suggests the diagnosis of lymphoblastic non-Hodgkin's lymphoma (LB-NHL) with moderate certainty. The presence of malignant cells in the pleural fluid and bone marrow makes the diagnosis certain. Thymomas on the other hand are more indolent, presenting with compressive symptoms in 20-30% of cases with pleural effusion and significant lymphadenopathy (2%) seen only rarely. In our case, the symptomatology and epidemiological characteristics of the disease placed a diagnosis of LB-NHL in good certainty (3-5).

Lymphoblastic lymphoma is diagnosed on FNA based on neoplastic cytomorphology with immunostaining for TdT and CD3, among other markers. Thymoma is a major non-neoplastic differential which is immunophenotypically similar. The presence of scattered cytokeratin positive thymic epithelial cells is diagnostic of lymphocyte-rich thymoma, which was the histopathologic diagnosis in our case (6,7). Diagnosis apart, FNA is also needed to characterize the type of lymphoma for the initiation of appropriate therapy.

The clinical presentation of our patient was confounded by the histopathologic picture. The lack of contributory evidence from the pleural fluid cytology and bone marrow biopsy made achieving the diagnosis harder still. Response to steroids made lymphoma a more probable scenario, though symptomatic thymomas have been reported to respond to steroids on multiple occasions (8,9). Considering the epidemiology, lack of evidence and the low rate of recurrence of a thymoma, allowing for further progression of the disease under close observation was the only feasible approach to attain the correct diagnosis leading to initiation of early and appropriate treatment.

Funding: None.

Conflict of Interest: The authors have no conflict of interest to disclose.

References

1. You MJ, Medeiros LJ, Hsi ED. T-lymphoblastic leukemia/lymphoma. *Am J Clin Pathol.* 2015; 144:411-422.
2. Mullen B, Richardson JD. Primary anterior mediastinal tumors in children and adults. *Ann Thorac Surg.* 1986; 42:338-345.
3. Carter BW, Marom EM, Detterbeck FC. Approaching the patient with an anterior mediastinal mass: a guide for clinicians. *J Thorac Oncol.* 2014; 9:S102-109.
4. Juanpere S, Cañete N, Ortuño P, Martínez S, Sanchez G, Bernado L. A diagnostic approach to the mediastinal masses. *Insights Imaging.* 2013; 4:29-52.
5. Ahmad U, Raja S. Lymph node metastases in thymic tumors: The more we know, the less we know. *J Thorac Cardiovasc Surg.* 2017; 154:e15-e16.
6. Li S, Juco J, Mann KP, Holden JT. Flow cytometry in the differential diagnosis of lymphocyte-rich thymoma from precursor T-cell acute lymphoblastic leukemia/lymphoblastic lymphoma. *Am J Clin Pathol.* 2004; 121:268-274.
7. Young NA, Al-Saleem T. Diagnosis of lymphoma by fine-needle aspiration cytology using the revised European-American classification of lymphoid neoplasms. *Cancer.* 1999; 87:325-345.
8. Barratt S, Puthuchery ZA, Plummeridge M. Complete regression of a thymoma to glucocorticoids, commenced for palliation of symptoms. *Eur J Cardiothorac Surg.* 2007; 31:1142-1143.
9. Patel E, Juan G, Vaidya A, Thomas A, Taillon J, Milan S, Gross L, Shahzad S. Near complete resolution of invasive thymoma with corticosteroid therapy. *Chest.* 2015; 148:421A.

Received May 4, 2020; Revised September 15, 2020; Accepted October 24, 2020.

**Address correspondence to:*

Animesh Ray, Department of Medicine, Third floor, Teaching block, All India Institute of Medical Sciences, New Delhi – 110029, India.

E-mail: doctoranimeshray@gmail.com

Released online in J-STAGE as advance publication October 29, 2020.