

Complete trisomy 9 detected by noninvasive prenatal testing and confirmed by amniocentesis

Feixiang Huang¹, Jing Zhou², Zheyun Xu³, Qing Qi², Hongmei Sun², Lei Chen^{4,*},
Ling Wang^{2,*}

¹ Department of Traditional Chinese Medicine, Hangzhou Women's Hospital, Hangzhou, Zhejiang, China;

² Department of gynecology, Obstetrics and Gynecology Hospital of Fudan University, Shanghai, China;

³ Zhejiang Chinese medical university, Hangzhou, Zhejiang, China;

⁴ Ultrasonography Department, Hangzhou Women's Hospital, Hangzhou, Zhejiang, China.

SUMMARY Complete chromosome 9 trisomy (T9) is a rare and fatal chromosomal disorder. We performed non-invasive prenatal testing (NIPT) in a patient with threatened abortion symptoms and found that the fetal was at risk for complete chromosome 9 trisomy. This shows that NIPT has certain accuracy in detecting trisomy of chromosome 9, which provide options for prenatal diagnosis of rare chromosomal abnormalities.

Keywords noninvasive prenatal testing, amniocentesis, complete trisomy 9, early threatened abortion

Letter to the Editor,

Complete T9 which means trisomy of the whole chromosome 9 with no evidence of mosaicism is rarely been reported. This rare aneuploidy, accounts for only 2.7 percent of all trisomy, usually leads to early pregnancy miscarriage (1). In rare cases, when the babies are born alive, they usually die during the neonatal period (2,3).

On September 16, 2019, a 26-year old female (gravida 1, para 0) patient at 19 week of pregnancy was admitted to our hospital due to abnormality of chromosome 9. There was no history of present disease and the family history was unremarkable. Ultrasonography performed at 7, 3/7 and 12, 1/7 week of pregnancy showed normal results. Early serological screening at 12,3/7 week of pregnancy showed the risk of trisomy 18 was high at 1: 119 (Greater than or equal to 1/460 is high risk), and the risks of trisomy 21 and trisomy 13 were low. Non-invasive prenatal testing (NIPT) at 14,5/7 wk of pregnancy suggested an abnormal Z-score of fetal chromosome 9 at 15.340 (the normal range was Z-score > 3 or < 3). The result of amniocentesis performed at 19 week of pregnancy found the final karyotyping of the fetus was 47, XX, +9, and complete T 9 was confirmed. Transabdominal level II ultrasound performed at 21, 6/7 wk of gestation showed intrauterine growth restriction (IUGR), enlargement of anterior fontanelle (Figure 1A), widened eye distance (Figure 1B), cleft lip and palate (Figures 1C and 1D), high echo of left kidney has, widened renal

collecting system and missing image of right renal echo (Figure 1E). Transverse section of the bladder, with only one umbilical artery visible on the right side of the fetus. In transverse view of the bladder, only one umbilical artery was observed at the right (Figure 1F). The four-chamber view revealed heart enlargement (Figure 1G) and pulmonary artery broadening (Figure 1H). No gallbladder echo was found in this test, that means absence of the gallbladder.

The patient requested termination of the pregnancy. At 22,1/7 week of pregnancy, the patient received ultrasound-guided amniotic cavity 6, 9-diamino-2-ethoxylacridine lactate hydrate (Rivanol, Guangxi Hefeng Pharmaceutical Co., Ltd., China) injection for labor induction. The fetus was stillborn 1 day after Rivanol injection.

NIPT for fetal chromosome detection has been widely used in recent years for further prenatal confirmation (4). It is mainly used for screening T21, T18, and T13 (5) and the use of NIPT in detecting T9 is rarely reported. The chromosome 9 abnormality suggested by NIPT in our case was consistent with the results of late amniocentesis. It is suggested that NIPT has accuracy in the early detection of complete T9. In addition, compared with amniocentesis which is suitable at 15-22 weeks of gestation, and umbilical vein puncture which is suitable at late than 18 weeks of gestation (6), NIPT can be used in early gestational weeks with higher security for it doesn't increase the rate of miscarriage and has no contraindications (7).

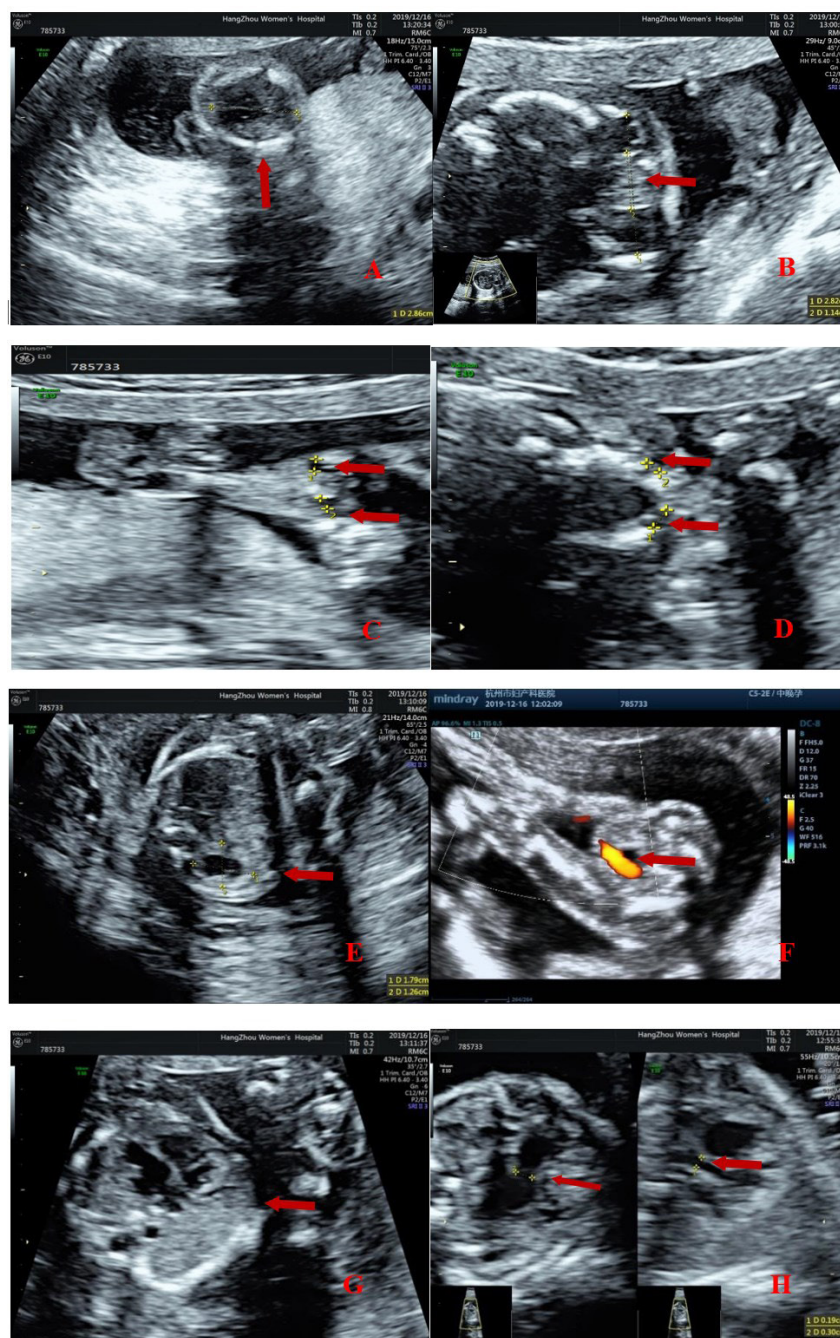


Figure 1 Imaging findings. (A) The arrow denotes the site of large anterior fontanelle, (B) widened eye distance, (C) cleft lip, (D) cleft palate, (E) widened renal collecting system, (F) Single umbilical artery, (G) large heart and (H) Widened pulmonary artery.

It has been reported that the fetal free DNA can be detected as early as 5 weeks of gestation in peripheral blood of pregnant women, and the detection rate is higher in the second trimester (8). Compared with transabdominal chorionic villus sampling (TA-CVS) that can be performed in the earlier gestational weeks (10-14 weeks) (9), NIPT is a non-invasive operation, while the TA-CVS has certain effects on the fetus such as fetal extremity developmental impairment, abortion, *etc.* (10). Our case reported a complete T9 with signs of threatened abortion, detected by NIPT, finally confirmed by amniocentesis and ultrasonic testing. To our knowledge, there is no similar literature at present. And it indicates that NIPT can be used for early detection of complete T9.

Funding: This work was supported by grants from a project from Kunpeng talent plan of Hangzhou Women's Hospital (to FX Huang), a project from Hangzhou municipal health commission for new talent in the medical industry (to FX Huang), a project of the National Science Foundation of Gansu province (grant No. 23JRRG0009 to HM Sun), a project of the Innovation Foundation of Higher Education of Gansu Province (grant No. 2021B-239 to HM Sun), a project of the Chinese Association of Integration of Traditional and Western Medicine special foundation for Obstetrics and Gynecology (grant No. FCK-ZSYTW-04 to Q Qi), a project under the Scientific and Technological Innovation Action Plan of the Shanghai Natural Science Fund (grant No. 20ZR1409100 to L Wang), a project

of the Chinese Association of Integration of Traditional and Western Medicine special foundation for Obstetrics and Gynecology-PuZheng Pharmaceutical Foundation (grant No. FCK-PZ-08 to L Wang), a project for hospital management of the Shanghai Hospital Association (grant No. X2021046 to L Wang) and a clinical trial project of the Special Foundation for Healthcare Research of the Shanghai Municipal Health Commission (grant No. 202150042 to L Wang).

Conflict of Interest: The authors have no conflicts of interest to disclose.

References

1. Chitayat D, Hodgkinson K, Luke A, Winsor E, Rose T, Kalousek D. Prenatal diagnosis and fetopathological findings in five fetuses with trisomy 9. *Am J Med Genet.* 1995; 56:247-251.
2. Feingold M, Atkins L. A case of trisomy 9. *J Med Genet.* 1973; 10:184-187.
3. Kannan TP, Hemlatha S, Ankathil R, Zilfalil BA. Clinical manifestations in trisomy 9. *Indian J Pediatr.* 2009; 76:745-746.
4. Du Y, Lin J, Lan L, Dong Y, Zhu J, Jiang W, Pan X, Lu Y, Li D, Wang L. Detection of chromosome abnormalities using current noninvasive prenatal testing: A multi-center comparative study. *Biosci Trends.* 2018; 12:317-324.
5. Faycal G, Bianchi DW. Noninvasive prenatal testing creates an opportunity for antenatal treatment of Down syndrome. *Prenat Diagn.* 2013; 33:614-618.
6. Alfirevic Z. Early amniocentesis versus transabdominal chorion villus sampling for prenatal diagnosis. *Cochrane Database Syst Rev.* 2007; 18:CD000077.
7. Odibo AO, Gray DL, Dicke JM, Stamilio DM, Macones GA, Crane JP. Revisiting the fetal loss rate after second-trimester genetic amniocentesis. *Obstet Gynecol.* 2008; 111:589-595.
8. Floyd E, Allyse MA, Michie M. Spanish and English-speaking pregnant women's views on cfDNA and other prenatal screening: Practical and ethical reflections. *J Genet Couns.* 2016; 25:965-977.
9. Firth HV, Boyd PA, Chamberlain PF, MacKenzie IZ, Morriss-Kay GM, Huson SM. Analysis of limb reduction defects in babies exposed to chorionic villus sampling. *Lancet.* 1994; 343:1069-1071.
10. Cederholm M, Haglund B, Axelsson O. Infant morbidity following amniocentesis and chorionic villus sampling for prenatal karyotyping. *BJOG.* 2005; 112:394-402.

Received July 18, 2023; Revised September 18, 2023; Accepted September 22, 2023

**Address correspondence to:*

Lei Chen, Department of Hangzhou Women's Hospital, No. 369 Kunpeng Road, Shangcheng District, Hangzhou 310008, Zhejiang, China.

E-mail: fxhuang2009@163.com

Ling Wang, Laboratory for Reproductive Immunology, Obstetrics and Gynecology Hospital of Fudan University, 419 Fangxie Road, Shanghai 200011, China.

E-mail: dr.wangling@fudan.edu.cn.

Released online in J-STAGE as advance publication October 11, 2023.