

# The comparative study of acetyl-11-keto-beta-boswellic acid (AKBA) and aspirin in the prevention of intestinal adenomatous polyposis in *APC<sup>Min/+</sup>* mice

Ruiqi Wang<sup>1</sup>, Yan Wang<sup>2</sup>, Zuhua Gao<sup>3,\*</sup>, Xianjun Qu<sup>1,\*</sup>

<sup>1</sup> Department of Pharmacology, School of Pharmaceutical Sciences, Shandong University, Jinan, China;

<sup>2</sup> Department of Pharmacology, Institute of Materia Medica, Shandong Academy of Medical Sciences, Jinan, China;

<sup>3</sup> Department of Pathology, McGill University, Montreal, Quebec, Canada.

## Summary

Acetyl-11-keto-beta-BA (AKBA), a component of the gum resin of *Boswellia serrata*, has been recognized as a promising agent for the prevention of intestinal tumorigenesis. Aspirin, a non-steroidal anti-inflammatory drug (NSAID), has also been considered to have the activity against intestinal tumorigenesis. However, the prevention of colonic cancer is insufficient and no definitive recommendation has been made for clinic use. Herein, we compared the efficacy of AKBA with that of aspirin in an adenomatous polyposis coli intestinal neoplasia (*APC<sup>Min/+</sup>*) mouse model. *APC<sup>Min/+</sup>* mice were administered AKBA or aspirin orally for 7 consecutive weeks. Mice were sacrificed by anesthetizing. The whole intestine was removed from each mouse. The number, size and histopathology of intestinal adenomatous polyps were examined under microscopy. The adenomatous polyps were removed for further analysis by the assays of western blotting and immunohistochemical staining. AKBA significantly prevented the formation of intestinal adenomatous polyps without toxicity to mice. Statistical analysis indicated that AKBA's activity both in the prevention of small intestinal and colonic polyps was more potently than aspirin. Histopathologic examination revealed that AKBA's effect, that is the reduction of polyp size and degree of dysplasia, was more prominent in larger sized polyps, especially those originating in colon. These effects of AKBA were associated with its role in the induction of apoptosis in carcinomas. The assays of western blotting and immunohistochemistry staining indicated that the efficacy of AKBA might arise from its activity in the modulation of the Wnt/ $\beta$ -catenin pathway and NF- $\kappa$ B/COX-2 pathway in adenomatous polyps. Conclusion, AKBA by oral application prevented intestinal tumorigenesis more potential than aspirin.

**Keywords:** Acetyl-11-keto-beta-boswellic acid, aspirin, *APC<sup>Min/+</sup>* mouse model, intestinal adenomatous polyps, Wnt/ $\beta$ -catenin pathway, apoptosis

## 1. Introduction

Colorectal cancer (CRC) is the most common malignancy worldwide. CRC has been considered to develop through

a gradual series of histological changes of adenomatous polyps, called 'adenoma-carcinoma' sequence. Intestinal adenomatous polyps are thus believed to be major precursors of CRC. Epidemiologic studies indicate that almost half of the population will develop at least one benign adenomatous colonic polyp during life, with 3% of those cases going on to develop colorectal cancers (1). Further studies indicated that the mutations of adenomatous polyposis coli (*APC*) gene are responsible for the development of colorectal cancer in all familial adenomatous polyposis (FAP) cases and in 59% of sporadic colorectal cancer cases (2). Mutation of *APC* gene will cause the dysregulation of the Wnt/ $\beta$ -catenin

\*Address correspondence to:

Dr. Xianjun Qu, Department of Pharmacology, School of Pharmaceutical Sciences, Shandong University, Jinan, China.  
E-mail: qxj@sdu.edu.cn

Dr. Zuhua Gao, Department of Pathology, McGill University, Montreal, Quebec, Canada.  
E-mail: zu-hua.gao@mcgill.ca

signaling pathway in which accumulate high levels of  $\beta$ -catenin in nucleus and then lead to the transcription of many cell proliferation-related genes (3). Currently, a combination of surgery and chemotherapy is used to treat colon cancers. The 5-year survival expectation for CRC patients ranges from 93% for early stages to 8% in fully advanced stages. Unfortunately, only about 37% of patients are diagnosed at early stage (4). Thus, the chemoprevention regimen seems to be an attractive option for early stage of CRC.

Several drugs have been studied in this field. There is considerable evidence that nonsteroidal antiinflammatory drugs (NSAIDs), particularly aspirin, could reduce the risk of intestinal adenomatous polyps (5). The epidemiologic reports determined the anti-carcinogenic effects of aspirin in high-risk population of CRC (6). Clinical trials in patients with familial adenomatous polyposis showed that aspirin might reduce the risk of CRC through regression of intestinal adenomatous polyps (7). These studies suggested that aspirin might prevent adenocarcinoma growth through the mechanism of anti-inflammatory activity, e.g. the activities of COX-2 and 5-LOX (8). However, long-term use of aspirin is not free from toxicities. Some studies indicated that the risk-benefit profiles of aspirin for prevention of CRC are insufficient and no definitive recommendations can be made (9).

Boswellic acids (BAs) were a mixture of pentacyclic triterpene acids which isolated from the gum resin of *Boswellia serrata* (10). BAs have been used as anti-inflammation agents for the treatment of many diseases, such as chronic colitis, ulcerative colitis and osteoarthritis (11). Acetyl-11-keto-beta-BA (AKBA) is one of these BAs which have been considered to be most effective among these BAs. In our previous study, we found that AKBA by p.o. gavage prevented the formation of intestinal adenomatous polyposis in  $APC^{Min/+}$  mice. AKBA might exert its chemopreventive action through multiple mechanisms including anti-proliferation, apoptosis induction, anti-inflammation and anti-angiogenesis (12). In this study, we compared these effects of AKBA with that of aspirin in the prevention of intestinal adenomatous polyposis in  $APC^{Min/+}$  mice.

## 2. Materials and Methods

### 2.1. Drugs

AKBA was purchased from Sigma-Aldrich (A9855). The purity of AKBA was 99.5%. Aspirin (A5376) was also purchased from Sigma-Aldrich with  $\geq 99.0\%$  purity. AKBA and aspirin were both suspended in 0.5% sodium carboxymethyl cellulose (CMC) in sterile water before application.

### 2.2. $APC^{Min/+}$ mouse model and drug application

$APC^{Min/+}$  male mice were obtained from Jackson Laboratories, USA. In our group,  $APC^{Min/+}$  male mice were crossed with wild type C57BL/6 female mice to generate  $APC^{Min/+}$  mice (12). A total of 18 male mice (age, 4 weeks) were randomly divided into three groups. After one week of acclimation, the mice were administrated with the vehicle control (0.5% CMC, w/v), AKBA 80 mg/kg and aspirin 80 mg/kg. Drugs and vehicle were given by p.o. gavage daily (0.2 mL/10 g body weight) for 7 consecutive weeks. Mice were weighed weekly and observed daily for any signs of toxicity. This research protocol was approved by the Animal Care and Use Committee at Shandong University.

### 2.3. Quantification of macroscopic and microscopic intestinal adenomatous polyp

Mice were sacrificed by anesthetizing. After sacrifice, the whole intestine including small intestine and colon were removed from each mouse. The intestines were spread onto filter paper, opened longitudinally with fine scissors, and washed with saline. Adenomatous polyps on the intestines were counted, and their sizes were measured under a dissecting microscope. After counting, the intestines were fixed in formalin, embedded in paraffin and stained with hematoxylin and eosin for further examination.

### 2.4. Immunohistochemistry staining assay

Immunohistochemistry staining assay was performed to analyze the expressions of  $\beta$ -catenin, cyclin D1, cyclooxygenase-2 (COX-2), and 5-LOX in the adenomatous polyps. Paraffin-embedded sections (4  $\mu$ m thick) were cut from formalin-fixed intestinal adenomatous polyps. After deparaffinization, the immunohistochemistry staining assay was carried out as described previously (12,13). The primary antibodies included  $\beta$ -catenin (9562), COX-2 (4842), cyclin D1 (2922, Cell Signaling), 5-LOX (bs-0526R, Bioss, China). Second antibodies included anti-mouse IgG and anti-rabbit IgG (Santa Cruz).

The effects of AKBA or aspirin on the growth of adenomatous polyps were estimated by determining the levels of these proteins in adenomatous polyps. Positive staining with cyclin D1 was defined as brown staining in nuclei of adenomatous cells. The percentage of positive cells was calculated as described previously (14). Positive staining with COX-2 and 5-LOX was determined based on brown intensity in membrane, cytoplasm and nucleus of adenomatous cells (15).  $\beta$ -Catenin is a dynamic protein enriched in the membrane of normal cells and enters the nucleus and cytoplasm of adenomatous cells (16). We determined the brown intensity of  $\beta$ -catenin in the cytoplasm and nucleus of adenomatous cells. The levels of these

proteins were quantified by scoring the intensity as 0 (no staining), +1 (very weak), +2 (weak), +3 (moderate), and +4 (strong) in five randomly selected fields at 400× magnification in each sample (12).

### 2.5. TUNEL staining assay

The apoptotic cells in intestinal adenomatous polyps were determined by terminal deoxynucleotidyl transferase-mediated dUTP nick end labeling (TUNEL) staining using an *in situ* cell death detection kit (Roche, Germany). Serial 4- $\mu$ m sections of intestinal adenomatous polyps were prepared and the staining was performed according to manufacturer's instructions. Adenomatous cells with brown-stained nuclei were recognized as TUNEL positive (12). The proportion of apoptotic cells in 6 mice was scored in randomly chosen fields under a microscope.

### 2.6. Western blotting assay

Western blotting assay was performed to determine the expressions of proteins-related to tumorigenesis in intestinal adenomatous polyps. Adenomatous polyps were incubated with 50  $\mu$ L RIPA lysis buffer at 4°C for 30 min and then the lysates (30  $\mu$ g of protein per lane) were fractionated by SDS-PAGE. The proteins were electro-transferred onto PVDF membranes and detected using the primary antibodies as described previously (17). The primary antibodies included those specific for NF- $\kappa$ B (sc-8008), p-NF- $\kappa$ B Ser<sup>536</sup> (sc-33020), TOPO II $\beta$  (sc-25330, Santa Cruz), caspase-3 (9662), caspase-9 (9502),  $\beta$ -catenin (9562), COX-2 (4842), cyclin D1 (2922), p-c-Jun (3270), survivin (2808), cleaved PARP (9541), PCNA (2586),  $\beta$ -actin (5779-1, Cell Signaling), Wnt-2 (3169-1, Epitomics) and c-Myc (ab32072, Abcam). The PVDF membranes were washed in 0.05% Tween-20/TBS and then incubated with horseradish peroxidase-conjugated secondary antibody. The bound antibodies were visualized using an enhanced chemiluminescence reagent (Millipore) and quantified by densitometry using ChemiDoc XRS+ image analyzer (Bio-Rad). Densitometric analyses of bands were adjusted with  $\beta$ -actin as loading control.

### 2.7. Statistical analysis

Data were described as mean  $\pm$  S.D. Statistical analysis was done with SPSS/Win13.0 software (SPSS, Inc., Chicago, Illinois). Comparisons between *APC*<sup>Min/+</sup> control and AKBA-treated mice were conducted by two-tailed Student's *t* test. Comparison multiple groups were analyzed by one-way ANOVA and multiple between-group comparisons were performed using the S-N-K method. A *p* value less than 0.05 was considered statistically significant.

## 3. Results

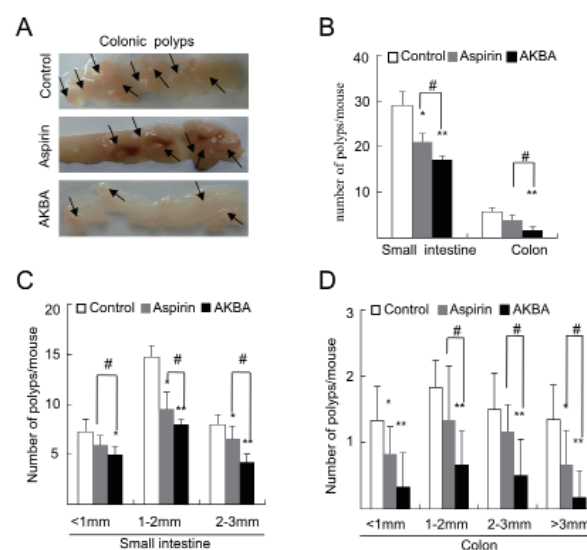
### 3.1. General observation

During the course of study, AKBA and aspirin were well tolerated by mice. There was no significant difference in body weight, peripheral blood element counts and other biological signs between AKBA or aspirin -treated and the vehicle control mice (data not shown)..

### 3.2. Prevention of intestinal adenomatous polyp formation by AKBA or aspirin

At age of 12 weeks, the number of adenomatous polyps in small intestine and colon of control mice were 29.0  $\pm$  2.9 and 5.8  $\pm$  1.0, respectively. Both AKBA and aspirin were found to have the activity against adenomatous polyp formation, whereas, AKBA's activity was more potently than aspirin. As shown in Figures 1A and 1B, treatment with AKBA resulted in the prevention of intestinal polyps by 45.7% and 78.7% (*p* < 0.01 vs. the vehicle control), respectively, in small intestines and colons. Aspirin prevented intestinal polyps by 27.6% (*p* < 0.05 vs. the vehicle control) in small intestines and 20.4% (*p* < 0.05 vs. the vehicle control) in colons. Statistical analysis indicated a significant difference between AKBA and aspirin (*p* < 0.05, Figures 1A and 1B).

The different efficacy of AKBA and aspirin was also observed by measuring the size of these adenomatous polyps. We divided the intestinal adenomatous polyps into four groups by small (< 1 mm), medium (1-2 mm), large (2-3 mm), and super large polyps (> 3 mm). In



**Figure 1. AKBA and aspirin prevented spontaneous intestinal polyposis in *APC*<sup>Min/+</sup> mice.** (A): representative images of colonic polyps; (B): the number of polyps per mouse in small intestine and colon; (C): the size distribution in small intestine. (D): the size distribution in small colon; \*, *p* < 0.05; \*\*, *p* < 0.01 versus the vehicle control; #, *p* < 0.05; ##, *p* < 0.01 versus aspirin. The bars represent mean  $\pm$  S.D. of six mice.

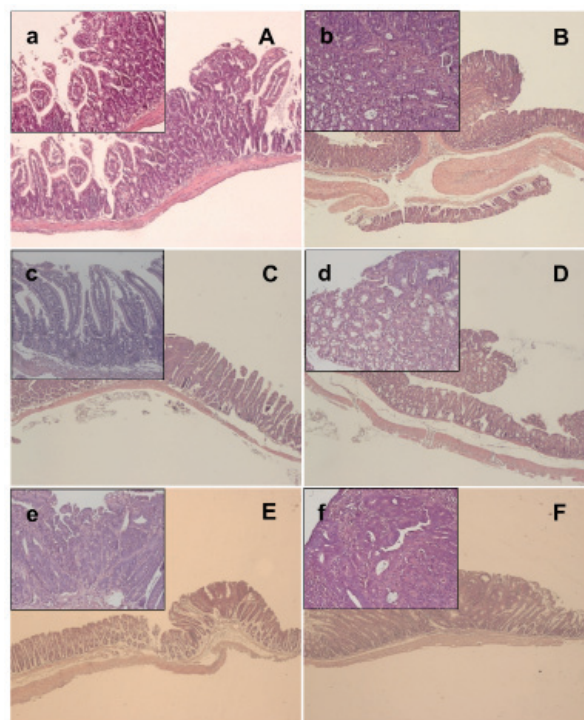
this study, we did not find super large polyps in small intestines. As shown in Figure 1C, the number of small, medium, and large polyps on small intestines were significantly prevented by 31.0% ( $p < 0.05$  vs. the vehicle control), 45.8% ( $p < 0.01$  vs. the vehicle control), and 52.5% ( $p < 0.01$  vs. the vehicle control), respectively, in the AKBA-treated mice; by 15.2% ( $p > 0.05$  vs. the vehicle control), 35.6% ( $p < 0.01$  vs. the vehicle control), and 18.7% ( $p < 0.05$  vs. the vehicle control), respectively, in the aspirin-treated mice. In colons, AKBA strongly reduced the number of small, medium, large polyps and super large polyps by 78.7% ( $p < 0.01$  vs. the vehicle control), 65.7% ( $p < 0.01$  vs. the vehicle control), 76.8% ( $p < 0.01$  vs. the vehicle control), and 84.5% ( $p < 0.01$  vs. the vehicle control), respectively; by 38.5% ( $p > 0.05$  vs. the vehicle control), 28.6% ( $p > 0.05$  vs. the vehicle control), 22.2% ( $p > 0.05$  vs. the vehicle control), 45.3% ( $p < 0.05$  vs. the vehicle control), respectively, by aspirin (Figure 1 D). A significant difference existed between these two groups of data from AKBA- and aspirin-treated mice ( $p < 0.05$ ).

### 3.3. AKBA exhibited more potential than aspirin in prevention of tumorigenesis and malignant progression of intestinal polyps

We examined the intestinal polyps by histopathologic analysis. Both AKBA and aspirin possessed the activity against tumorigenesis and malignant progression of intestinal polyps. In  $APC^{Min/+}$  mice, small intestinal polyps were determined to be adenomas, showing the crowded pencil-shaped hyperchromatic nuclei with preserved polarity and diminished mucin (Figure 2A). In colonic polyps, larger polyps were determined to be advanced adenomas, showing focal high grade dysplasia and intramucosal carcinomas demonstrated marked nuclear pleomorphism with lack of nuclear polarity (Figure 2B). The number of dysplastic cells and degree of dysplasia in each polyp was obviously reduced in the AKBA-treated mice (Figure 2C). High grade dysplasia or intramucosal carcinoma was not found in the AKBA-treated polyps. The interdigitated normal appearing intestinal villi were observed in these intestinal polyps (Figure 2C). AKBA effect, *i.e.* the decrease of polyp size and degree of dysplasia, was more prominent in the colonic polyps (Figure 2D). Aspirin also showed the effect of prevention tumorigenesis in small intestinal polyps and colonic polyps, whereas, its effect was not as well as AKBA in the prevention of intestinal tumorigenesis and malignant progression (Figures 2E and 2F).

### 3.4. AKBA had greater effect than aspirin in induction of apoptosis in intestinal adenocarcinomas

Examination of intestinal polyps by TUNEL staining assay indicated the apoptotic effect of AKBA and aspirin

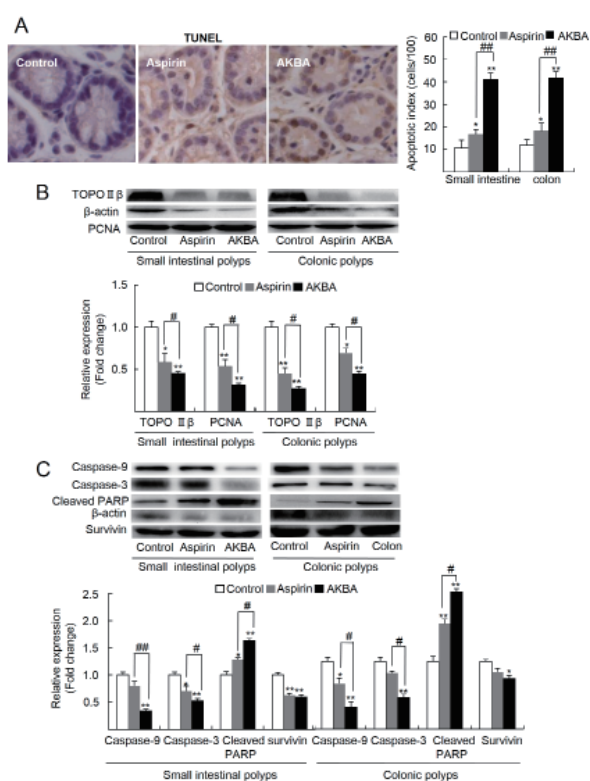


**Figure 2. The representative figures of the H&E-stained intestinal sections from control mice, AKBA- or aspirin-treated mice. (A):** The crater-shaped adenomatous polyps in small intestine of control  $APC^{Min/+}$  mice ( $\times 100$ ). **a'** (inset): adenomatous epithelium shows the enlarged, hyperchromatic, elongated and crowded dysplastic nuclei ( $\times 200$ ). **(B):** The adenomatous polyps with focal high grade dysplasia in colon of control  $APC^{Min/+}$  mice ( $\times 100$ ). **b'** (inset): the crypt architecture shows complex and the nuclei are pleomorphic with frequent mitoses. A lack of nuclear polarization was observed in the glands ( $\times 200$ ). **(C):** The small intestine in the AKBA-treated mice ( $\times 100$ ). **c'** (inset): Crypt architecture shows mostly normal with unremarkable epithelial nuclei ( $\times 200$ ). **(D):** The colon in the AKBA-treated mice ( $\times 100$ ). **d'** (inset): The structure and nuclei of epithelium shows mostly normal ( $\times 200$ ). **(E):** The small intestine in the aspirin-treated mice ( $\times 100$ ). **e'** (inset): part of crypt architectures were in their normal shape with unremarkable nuclei ( $\times 200$ ). **(F):** Colon in the aspirin-treated mice ( $\times 100$ ). **f'** (inset): some of the structure and nuclei of epithelium were in normal shape, whereas not as well as in the AKBA-treated colons ( $\times 200$ ).

on adenocarcinomas. As shown in Figure 3A, AKBA strongly increased the number of TUNEL-positive cells by 269.7% ( $p < 0.01$  vs. untreated control) in small intestinal polyps and 252.5% ( $p < 0.01$  vs. the vehicle control) in colonic polyps. Aspirin increased TUNEL staining cells by 56.6% ( $p < 0.05$  vs. the vehicle control), in small intestinal polyps, and by 54.2% ( $p < 0.05$  vs. the vehicle control), in colonic polyps. A significant difference existed between AKBA and aspirin ( $p < 0.05$ ).

Further analysis by western blotting assay suggested that these effects by AKBA might arise from its role of modulating the apoptotic-related proteins. As shown in Figure 3B, the levels of Topo III $\beta$  and PCNA in the AKBA-treated adenomatous polyps were significantly reduced by 54.7% ( $p < 0.01$  vs. the vehicle control), 68.7% ( $p < 0.01$  vs. vehicle control), respectively, in small intestinal polyps; by 72.7% ( $p < 0.01$  vs. the vehicle control), 55.3% ( $p < 0.01$  vs. the vehicle control),

respectively, in colonic polyps. Aspirin reduced the level of Topo II $\beta$  and PCNA by 41.6% ( $p < 0.05$  vs. the vehicle control), 40.8% ( $p < 0.01$  vs. the vehicle control), respectively, in small intestinal polyps and by 55.0% ( $p < 0.01$  vs. the vehicle control), 30.1% ( $p < 0.05$  vs. the vehicle control), respectively, in colonic polyps. Analysis of caspase-9, caspase-3, and cleaved PARP in the adenomatous polyps confirmed the AKBA's activity. As shown in Figure 3C, the levels of caspase-9, caspase-3, and survivin in the AKBA-treated polyps were significantly reduced by 65.4% ( $p < 0.01$  vs. the vehicle control), 41.2% ( $p < 0.01$  vs. the vehicle control) and 40.4% ( $p < 0.01$  vs. the vehicle control), respectively, in small intestinal polyps; and by 67.4% ( $p < 0.01$  vs. the vehicle control), 53.3% ( $p < 0.01$  vs. the vehicle control) and 28.3% ( $p < 0.05$  vs. the vehicle control), respectively, in colonic polyps. The level of cleaved PARP were strongly increased by 63.8% ( $p < 0.01$  vs. the vehicle control), 103.1% ( $p < 0.01$  vs. the vehicle control), respectively, in small intestinal polyps and colonic polyps. In the aspirin-treated mice, the levels of caspase-9, caspase-3 and survivin were reduced by 20.1% ( $p > 0.05$  vs. the vehicle control), 29.5% ( $p < 0.05$  vs. the vehicle control) and 36.0% ( $p < 0.01$  vs. the vehicle control), respectively, in small intestinal polyps;

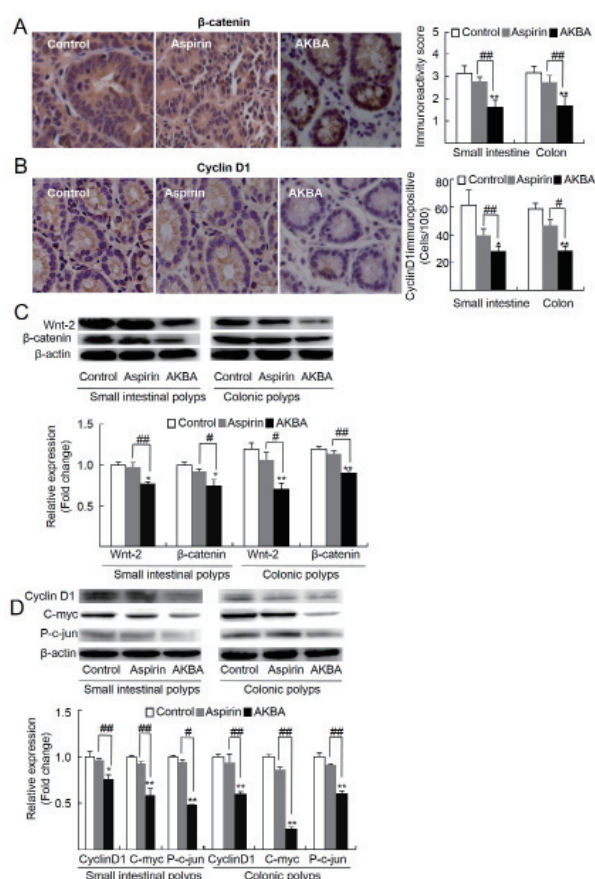


**Figure 3. AKBA and aspirin induced apoptosis of intestinal polyps.** (A): AKBA and aspirin increased TUNEL-positive cells in intestinal polyps as estimated by immunohistochemical staining assay ( $\times 400$ ). The bars represent mean  $\pm$  S.D. of six mice. (B) and (C): AKBA and aspirin modulated the expression of apoptotic related proteins in intestinal polyps as estimated by western blotting assay. Experiments were performed in triplicate separately. \*,  $p < 0.05$ ; \*\*,  $p < 0.01$  versus the vehicle control; #,  $p < 0.05$ ; ##,  $p < 0.01$  versus aspirin.

and by 32.7% ( $p < 0.05$  vs. the vehicle control), 19.7% ( $p > 0.05$  vs. the vehicle control), and 15.4% ( $p > 0.05$  vs. the vehicle control), respectively, in colonic polyps. The level of cleaved PARP were increased by 25.4% ( $p < 0.05$  vs. the vehicle control), 56.9% ( $p < 0.01$  vs. vehicle control), respectively, in small intestinal polyps and colonic polyps.

### 3.5. Modulation of the Wnt/ $\beta$ -catenin signaling pathway by AKBA

The expression levels of proteins in the Wnt/ $\beta$ -catenin signaling pathway were determined by the assays of immunochemical staining and western blotting. AKBA possessed the activity of modulating the Wnt/ $\beta$ -catenin pathway, whereas, aspirin did not significantly affect these proteins in this signaling pathway. In the AKBA-treated polyps, the level of  $\beta$ -catenin was strongly reduced by 49.0% ( $p < 0.01$  vs. the vehicle control) in small intestinal polyps, by 46.8% ( $p < 0.01$  vs. the vehicle control) in colonic polyps (Figure 4A). The



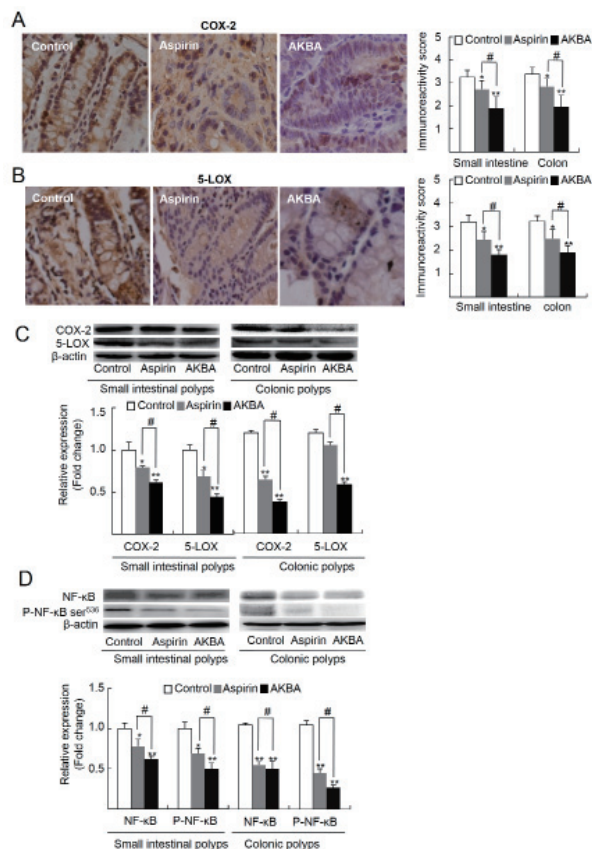
**Figure 4. AKBA modulated the Wnt/ $\beta$ -catenin pathway and its targets.** (A) and (B): The expressions of  $\beta$ -catenin and cyclin D1 in epithelia of intestinal polyps were examined by immunohistochemical assay ( $\times 400$ ). The bars represent mean  $\pm$  S.D. of six mice. (C) and (D): The expressions of Wnt-2,  $\beta$ -catenin and targets cyclin D1, c-Myc and p-c-jun in intestinal polyps were determined by western blotting assay. Experiments were performed in triplicate separately. \*,  $p < 0.05$ ; \*\*,  $p < 0.01$  versus the vehicle control; #,  $p < 0.05$ ; ##,  $p < 0.01$  versus aspirin.

level of cyclin D1 was significantly reduced by 54.9% ( $p < 0.05$  vs. the vehicle control) in small intestinal polyps, and by 50.6% ( $p < 0.01$  vs. the vehicle control) in colonic polyps, respectively (Figure 4B).

Western blotting assay further determined the levels of proteins in the Wnt/ $\beta$ -catenin signaling pathway and its downstream targets. In the AKBA-treated adenomatous polyps, the levels of Wnt-2 and  $\beta$ -catenin were significantly reduced by 33.1% ( $p < 0.05$  vs. the vehicle control) and 35.7% ( $p < 0.05$  vs. the vehicle control), respectively, in small intestinal polyps, and 41.2% ( $p < 0.01$  vs. the vehicle control) and 34.4% ( $p < 0.01$  vs. the vehicle control), respectively, in colonic polyps (Figure 4C). Figure 4D showed the levels of the downstream targets of the Wnt/ $\beta$ -catenin pathway. In the AKBA-treated adenomatous polyps, the levels of cyclin D1, c-Myc and p-c-jun were significantly decreased by 34.4% ( $p < 0.05$  vs. the vehicle control), 41.8% ( $p < 0.01$  vs. the vehicle control), 53.3% ( $p < 0.01$  vs. the vehicle control), respectively, in small intestine polyps; by 40.5% ( $p < 0.01$  vs. the vehicle control), 78.0% ( $p < 0.01$  vs. the vehicle control), and 49.8% ( $p < 0.01$  vs. the vehicle control), respectively, in colonic polyps. The levels of these proteins did not show significant changes in the aspirin-treated adenomatous polyps both in small intestines and colons ( $p > 0.05$  vs. the vehicle control).

### 3.6. AKBA had a great effect on suppression of inflammatory factors

We evaluated the inhibitory effect of AKBA in the suppression of inflammatory cytokines in adenomatous polyps. Immunohistochemical staining showed that both AKBA and aspirin possessed the activity of inhibition on COX-2, and 5-LOX expression (Figures 5A and 5B). We compared the density of immunohistochemical staining of COX-2 and 5-LOX in these adenomatous polyps. A greater inhibitory effect of AKBA on these inflammatory cytokines was observed as compared to that of aspirin ( $p < 0.05$ ). Similar profiles of the inhibitory effect on these cytokines were also determined in the AKBA- and aspirin-treated adenomatous polyps as evaluated by western blotting assay (Figure 5C). As shown in Figure 5D, the levels of p-NF- $\kappa$ B<sup>ser<sup>536</sup></sup> and NF- $\kappa$ B in the adenomatous polyps by AKBA were significantly reduced by 51.6% ( $p < 0.01$  vs. the vehicle control), 42.5% ( $p < 0.01$  vs. the vehicle control), respectively, in small intestines; by 74.4% ( $p < 0.01$  vs. the vehicle control), 52.3% ( $p < 0.01$  vs. the vehicle control), in colons. The levels of p-NF- $\kappa$ B<sup>ser<sup>536</sup></sup> and NF- $\kappa$ B in the aspirin-treated adenomatous polyps were reduced by 31.4% ( $p < 0.05$  vs. the vehicle control), 22.2% ( $p < 0.05$  vs. the vehicle control), respectively, in small intestines and 57.2% ( $p < 0.01$  vs. the vehicle control), 42.6% ( $p < 0.01$  vs. the vehicle control), respectively, in colons. These results indicated that AKBA possessed



**Figure 5. AKBA and aspirin suppressed inflammatory mediators in intestinal polyps.** (A) and (B): Immunohistochemical staining indicated the decrease of COX-2 (A) and 5-LOX (B) expressions in intestinal polyps ( $\times 400$ ). The bars represent mean  $\pm$  S.D. of six mice. (C) and (D): Western blotting showed the decrease of COX-2, 5-LOX, p-NF- $\kappa$ B ser<sup>536</sup> and NF- $\kappa$ B in the intestine polyps of AKBA- or aspirin-treated mice. Experiments were performed in triplicate separately. \*,  $p < 0.05$ ; \*\*,  $p < 0.01$  versus the vehicle control; #,  $p < 0.05$ ; ##,  $p < 0.01$  versus aspirin.

greater activity than aspirin in the suppression these inflammatory stimuli in intestinal adenomatous polyps.

## 4. Discussion

AKBA, a naturally occurring, orally active pentacyclic triterpenoid extracted from *boswellia serrata*, was initially determined for its anti-inflammatory properties and used for the treatment of many chronic inflammation diseases (18). Recent studies have highlighted its role in anti-cancer properties. AKBA by oral administration in mice could change intestinal microenvironment, prevent stroma and epithelial cell growth (12). In this study, we determined the inhibitory effect of AKBA in the adenomatous polyposis coli multiple intestinal neoplasia (*APC<sup>Min/+</sup>*) mouse model and then compared these results with those of aspirin. AKBA was found to have higher efficacy than aspirin in the prevention of intestinal adenomatous polyposis development. Our statistical analysis suggested that the inhibitory effect of AKBA might arise from its multiple actions including anti-proliferation, induction

of apoptosis, modulation of the Wnt/ $\beta$ -catenin signaling pathway, and anti-inflammation. These results supported our previous results that AKBA could develop as a promising agent for the prevention of intestinal tumorigenesis (12).

The development of intestinal tumorigenesis is a gradual series of histological changes, called the 'adenomatous polyps-carcinoma' sequence. This sequence has been mostly considered to arise from the mutation of adenomatous polyposis coli (*APC*) gene (19). In the *APC*<sup>Min/+</sup> mouse model, the mutation of APC gene leads to the dysregulation of the Wnt/ $\beta$ -catenin signaling pathway in which accumulated  $\beta$ -catenin in nucleus leads to transcription of many its target genes. These target genes are amplified following the activation of the aberrant Wnt/ $\beta$ -catenin signaling pathway (20,21). Among the targets of  $\beta$ -catenin, PCNA is a marker of cell proliferation and is highly expressed during the 'adenomatous polyps-carcinoma' sequence. Cyclin D1 is a cell cycle protein frequently overexpressed in adenomatous polyps. A high level of c-Myc stimulates cell proliferation and prevents apoptosis in adenomatous polyps. c-Myc and cyclin D1 have also been identified as the transactivation targets of the  $\beta$ -catenin-TCF complex through binding site in their promoter region. Survivin is a prominent anti-apoptotic molecule widely expressed in adenomatous cells. Overexpression of survivin could lead to adenomatous proliferation (22,23). The *APC*<sup>Min/+</sup> mouse model is thus widely used for evaluation of chemopreventive agents. AKBA possessed strong activity of modulating the Wnt/ $\beta$ -catenin pathway and many of its target proteins, including cyclin D, PCNA, survivin, c-Myc, and p-c-jun. In this study, we did not find significant changes of proteins in Wnt/ $\beta$ -catenin pathway in the aspirin-treated adenomatous polyps. We thus suggested that AKBA might be an inhibitor of the Wnt/ $\beta$ -catenin signaling pathway.

In colonic adenocarcinomas, the inflammatory microenvironment is characterized by the presence of inflammatory stimuli including cytokines and network of growth factors both supporting stroma and adenomatous areas (24,25). These stimuli contribute to adenocarcinoma expansion, and even facilitate the metastatic process. Important inflammatory stimuli include COX-2, NF- $\kappa$ B, 5-LOX, PGEs, LTB<sub>4</sub>, IL-6, TNF- $\alpha$ , FGF-2, and iNOS *etc.* (12,26). NF- $\kappa$ B is considered as a 'first responder' to various types of cellular stress. NF- $\kappa$ B activation could induce I $\kappa$ B phosphorylation, targeting it for degradation through an ubiquitin-proteasome pathway, releasing NF- $\kappa$ B to enter the nucleus, where it regulates gene expression. COX-2 is an immediate-early growth response gene product. In response to stimulation of these cytokines, the intercellular communications of the NF- $\kappa$ B-COX-2 pathway take place and lead to adenocarcinoma growth. The accumulation of these molecules further

stimulates the Wnt/ $\beta$ -catenin signaling pathway, leading to expansion of adenomatous polyps (27). 5-LOX is a key enzyme in metabolizing arachidonic acid to leukotrienes which act quickly to promote the progression of intestinal polyps through activation of NF- $\kappa$ B. High levels of 5-LOX directly stimulate angiogenesis, proliferation and anti-apoptosis in adenomatous polyps (26). In addition, COX-2 and 5-LOX are usually co-expressed and up-regulated in the intestinal adenomatous polyps (12). Aspirin has long been considered to have the activity of anti-inflammation through the mechanisms of suppressing COX-2 and prostaglandin E<sub>2</sub> (PGE<sub>2</sub>) (5,6). Recent studies suggested that aspirin might possess the activity against intestinal adenocarcinomas. The mechanism of aspirin action has been considered to be associated with its anti-inflammation activity. In this study, we compared the efficacy and mechanisms of AKBA with those of aspirin. AKBA possessed a greater activity than aspirin in the suppression of these inflammatory cytokines. These findings suggest that administration of AKBA might have a more beneficial effect than aspirin in prevention of colon adenocarcinoma growth.

In conclusion, AKBA significantly prevented the formation of intestinal adenomatous polyposis without toxicity to mice. Our comparative study suggested that AKBA possess more potential than aspirin in anti-proliferation, induction of apoptosis, modulation of the Wnt/ $\beta$ -catenin pathway, and anti-inflammation. These results support our previous results that AKBA could develop as a promising agent in prevention of colorectal adenocarcinomas.

#### Acknowledgements

This project was supported by the Natural Science Foundation of China (Grant nos. 91229113, 81173090, and 81072665).

#### References

1. Cunningham D, Atkin W, Lenz HJ, Lynch HT, Minsky B, Nordlinger B, Starling N. Colorectal cancer. Lancet. 2010; 375:1030-1047.
2. Samowitz WS, Slattery ML, Sweeney C, Herrick J, Wolff RK, Albertsen H. APC mutations and other genetic and epigenetic changes in colon cancer. Mol Cancer Res. 2007; 5:165-170.
3. Senda T, Iizuka-Kogo A, Onouchi T, Shimomura A. Adenomatous polyposis coli (*APC*) plays multiple roles in the intestinal and colorectal epithelia. Med Mol Morphol. 2007; 40:68-81.
4. Manzano A, Pérez-Segura P. Colorectal cancer chemoprevention: Is this the future of colorectal cancer prevention? ScientificWorldJournal 2012; 2012:327341.
5. Rothwell PM, Wilson M, Price JF, Belch JF, Meade TW, Mehta Z. Effect of daily aspirin on risk of cancer metastasis: A study of incident cancers during randomised controlled trials. Lancet. 2012; 379:1591-1601.

6. Cuzick J, Otto F, Baron JA, Brown PH, Burn J, Greenwald P, Jankowski J, La Vecchia C, Meyskens F, Senn HJ, Thun M. Aspirin and non-steroidal anti-inflammatory drugs for cancer prevention: an international consensus statement. *Lancet Oncol*. 2009; 10:501-507.
7. Sandler RS, Halabi S, Baron JA, Budinger S, Paskett E, Keresztes R, Petrelli N, Pipas JM, Karp DD, Loprinzi CL, Steinbach G, Schilsky R. A randomized trial of aspirin to prevent colorectal adenomas in patients with previous colorectal cancer. *N Engl J Med*. 2003; 348:883-890.
8. Garcia-Albeniz X, Chanm AT. Aspirin for the prevention of colorectal cancer. *Best Pract Res Clin Gastroenterol*. 2011; 25:461-472.
9. Baron JA, Cole BF, Sandler RS, Haile RW, Ahnen D, Bresalier R, McKeown-Eyssen G, Summers RW, Rothstein R, Burke CA, Snover DC, Church TR, Allen JI, Beach M, Beck GJ, Bond JH, Byers T, Greenberg ER, Mandel JS, Marcon N, Mott LA, Pearson L, Saibil F, van Stolk RU. A randomized trial of aspirin to prevent colorectal adenomas. *N Engl J Med*. 2003; 348:891-899.
10. Sengupta K, Kolla JN, Krishnaraju AV, Yalamanchili N, Rao CV, Golakoti T, Raychaudhuri S, Raychaudhuri SP. Cellular and molecular mechanisms of anti-inflammatory effect of Aflapin: A novel *Boswellia serrata* extract. *Mol Cell Biochem*. 2011; 354:189-197.
11. Singh S, Khajuria A, Taneja SC, Johri RK, Singh J, Qazi GN. Boswellic acids: A leukotriene inhibitor also effective through topical application in inflammatory disorders. *Phytomedicine*. 2008; 15:400-407.
12. Liu HP, Gao ZH, Cui SX, Wang Y, Li BY, Lou HX, Qu XJ. Chemoprevention of intestinal adenomatous polyposis by acetyl-11-keto-beta-boswellic acid in *APC<sup>Min/+</sup>* mice. *Int J Cancer* 2013; 132:2667-2681.
13. Nishi H, Inoue Y, Kageshita T, Takata M, Ihn H. The expression of human high molecular weight melanoma-associated antigen in acral lentiginous melanoma. *Biosci Trends*. 2010; 4:86-89.
14. Hu R, Khor TO, Shen G, Jeong WS, Hebbar V, Chen C, Xu C, Reddy B, Chada K, Kong AN. Cancer chemoprevention of intestinal polyposis in *APC<sup>Min/+</sup>* mice by sulforaphane, a natural product derived from cruciferous vegetable. *Carcinogenesis*. 2006; 27:2038-2046.
15. Rajamanickam S, Velmurugan B, Kaur M, Singh RP, Agarwal R. Chemoprevention of intestinal tumorigenesis in *APC<sup>Min/+</sup>* mice by silibinin. *Cancer Res*. 2010; 70:2368-2378.
16. Sundram V, Chauhan SC, Ebeling M, Jaggi M. Curcumin attenuates  $\beta$ -catenin signaling in prostate cancer cells through activation of protein kinase D1. *PLoS One* 2012; 7:e35368.
17. Park EJ, Shin JW, Seo YS, Kim DW, Hong SY, Park WI, Kang BM. Gonadotropin-releasing hormone-agonist induces apoptosis of human granulosa-luteal cells via caspase-8, -9 and -3, and poly-(ADP-ribose)-polymerase cleavage. *Biosci Trends*. 2011; 5:120-128.
18. Singh S, Khajuria A, Taneja SC, Johri RK, Singh J, Qazi GN. Boswellic acids: A leukotriene inhibitor also effective through topical application in inflammatory disorders. *Phytomedicine*. 2008; 15:400-407.
19. McCart AE, Vickaryous NK, Silver A. Apc mice: models, modifiers and mutants. *Pathol Res Pract*. 2008; 204:479-490.
20. Cheung AF, Carter AM, Kostova KK, Woodruff JF, Crowley D, Bronson RT, Haigis KM, Jacks T. Complete deletion of Apc results in severe polyposis in mice. *Oncogene*. 2010; 29:1857-1864.
21. Hawkes WC, Alkan Z. Delayed cell cycle progression from SEPW1 depletion is p53- and p21-dependent in MCF-7 breast cancer cells. *Biochem Biophys Res Commun*. 2011; 413:36-40.
22. Kühl SJ, Kühl M. On the role of Wnt/ $\beta$ -catenin signaling in stem cells. *Biochim Biophys Acta*. 2012; 1830:2297-2306.
23. Takahashi-Yanaga F, Sasaguri T. Drug development targeting the glycogen synthase kinase-3beta (GSK-3beta)-mediated signal transduction pathway: Inhibitors of the Wnt/beta-catenin signaling pathway as novel anticancer drugs. *J Pharmacol Sci*. 2009; 109:179-183.
24. Ullman TA, Itzkowitz SH. Intestinal inflammation and cancer. *Gastroenterology*. 2011; 140:1807-1816.
25. Zamri N, Masuda N, Oura F, Yajima Y, Nakada H, Fujita-Yamaguchi Y. Effects of two monoclonal antibodies, MLS128 against Tn-antigen and 1H7 against insulin-like growth factor-I receptor, on the growth of colon cancer cells. *Biosci Trends*. 2012; 6:303-312.
26. Aggarwal BB, Shishodiam S, Sandur SK, Pandey MK, Sethi G. Inflammation and cancer: hHow hot is the link? *Biochem Pharmacol*. 2006; 72:1605-1621.
27. Rao CV. Nitric oxide signaling in colon cancer chemoprevention. *Mutat Res*. 2004; 555:107-119.

(Received January 21, 2014; Accepted February 1, 2014)