

Management of inappropriate sinus tachycardia with ivabradine in a renal transplant recipient

Vipin Kumar Goyal^{1,*}, Suraj Godara², Trilok Chandra Sadasukhi³, Hoti Lal Gupta³

¹ Department of Anaesthesia and Critical Care, Mahatma Gandhi Medical College and Hospitals, Jaipur, Rajasthan, India;

² Department of Nephrology, Mahatma Gandhi Medical College and Hospitals, Jaipur, Rajasthan, India;

³ Department of Urology, Mahatma Gandhi Medical College and Hospitals, Jaipur, Rajasthan, India.

Summary Inappropriate sinus tachycardia (IST) is a syndrome characterized by unexplained tachycardia (heart rate > 100 beats /min) and related symptoms at rest. We describe a case of a 35 year old male with end stage renal disease who developed IST after renal transplant in the surgical intensive care unit. Management of IST is usually nonspecific and includes bradycardic agents, radiofrequency ablation or surgical ablation of the sinus node. This patient was well managed with ivabradine (I_f pacemaker current inhibitor) after failure and intolerance of β -adrenergic blockers.

Keywords: Ivabradine, inappropriate sinus tachycardia, renal transplant

1. Introduction

Inappropriate sinus tachycardia (IST) is a very rare cardiac arrhythmia and classified in arrhythmias of supraventricular origin. Etiology is unclear, although sinus node dysfunction or dysautonomia may be the causative factors. Treatment options are very few and mostly ineffective.

2. Case report

We report a case of IST in a 35 year old male who had undergone renal transplant for chronic kidney disease. Patient had a history of chronic kidney disease (grade IV) and was on hemodialysis. No other medical risk factor was present except hypertension for 1 month that was well controlled with tablet amlodipine 5 mg OD. His preoperative routine blood investigations were within normal range except for increased renal function tests and low hemoglobin. Electrocardiogram showed sinus rhythm with heart rate 84 beats/min, ST depression in lead I, V1-V6 and P mitrale. Echocardiography showed ejection fraction

50% with moderate PAH, moderate MR and diastolic dysfunction grade III. Patient's exercise tolerance was good and vital parameters were stable (blood pressure 154/96 mmHg and heart rate 86 beats/min) (Figure 1). Surgery was performed under general anesthesia and patient was shifted to post operative intensive care unit. Hemodynamics were stable throughout intraoperative period. About 10 h after surgery patient developed an episode of sinus tachycardia with heart rate of 120-140 beats/min that was persistent and associated with palpitations, perspiration, sensation of burning in chest and a slight fall in blood pressure (Figure 2). Probable etiologic factors for sinus tachycardia in postoperative period like pain, hypovolemia, hypotension, increased temperature, blood loss, anxiety, and drugs were ruled out. Serum electrolyte and acid base and gas analysis reports were nonsignificant. Repeated injection of metoprolol was tried in an interval but the effect was nonsustained along with a dramatic fall in blood pressure. Calcium channel blockers were not tried in view of interaction of these agents with immunosuppressive agents. Tablet ivabradine 5 mg orally was started as next line of management on a trial and error basis. After half an hour of ivabradine administration, heart rate dropped to 76 - 85 beats/min and remained sustained without significant change in blood pressure. We continued ivabradine 5 mg orally twice a day for 5 days. No further episode of tachycardia was recorded after discontinuation of ivabradine.

*Address correspondence to:

Dr. Vipin Kumar Goyal, Department of Anaesthesia and Critical Care, Mahatma Gandhi Medical College and Hospitals, Jaipur, Rajasthan, India.
E-mail: dr.vipin28@gmail.com

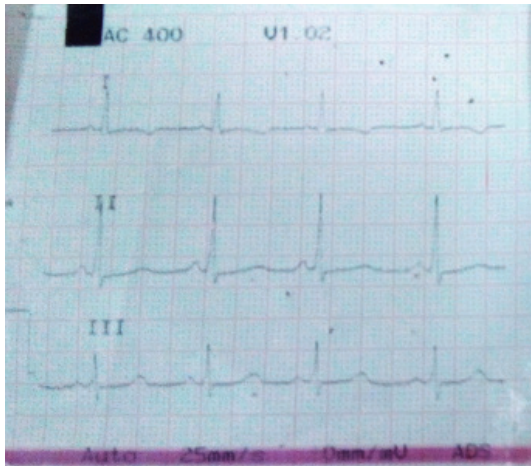


Figure 1. Showing sinus rhythm with heart rate 86 beats/min in preoperative ECG.

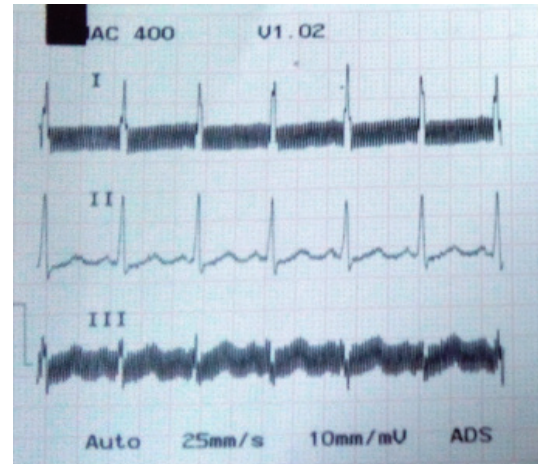


Figure 2. Showing sinus rhythm with heart rate 125 beats/min in postoperative period.

3. Discussion

Sinus tachycardia can be of multiple origins in the postoperative period and is usually well controlled with correction of etiologic factors. Inappropriate sinus tachycardia is a rare entity of unknown origin defined as recurrent or persistent tachycardia with or without associated symptoms. IST is usually associated with symptoms like palpitations, hypotension, dizziness, fatigue, weakness, syncope, etc. Diagnosis is based on 12 lead electrocardiogram and exclusion of other possible etiologic factors like anxiety, pain, medications, fever, anemia, dehydration, hyperthyroidism, pheochromocytoma, pneumothorax, etc. Management of IST is a challenge as no clearly defined treatment is present and it is completely based on a trial and error basis. Ivabradine is a selective and specific inhibitor of the hyperpolarization activated pacemaker current (I_f) that controls spontaneous diastolic depolarization in the sinus node and regulates heart rate (6). Until now, it was used for treatment of patients with chronic stable angina or chronic heart failure. Ivabradine can be used as an alternative to β blockers and calcium channel blockers for management of IST when these agents are not tolerated or overdose is to be avoided (1-5). Only a few research articles and case reports are available mentioning its use to control heart rate in patients with IST.

In our case IST was managed successfully with ivabradine without any untoward adverse effect as seen with β blockers.

References

1. Olshansky B, Sullivan RM. Inappropriate sinus tachycardia. *J Am Coll Cardiol.* 2013; 61:793-801.
2. Zellerhoff S, Hinterseer M, Felix Krull B, Schulze-Bahr E, Fabritz L, Breithardt G, Kirchhof P, Kaab S. Ivabradine in patients with inappropriate sinus tachycardia. *Naunyn Schmiedebergs Arch Pharmacol.* 2010; 382:483-486.
3. Calo L, Rebecchi M, Sette A, *et al.* Efficacy of ivabradine administration in patients affected with inappropriate sinus tachycardia. *Heart Rhythm.* 2010; 7:1318-1323.
4. Schulze V, Steiner S, Hennersdorf M, Strauer B. Ivabradine as an alternative therapeutic trial in the therapy of inappropriate sinus tachycardia. *Cardiology.* 2008; 110:206-208.
5. Yusuf S, Camm AJ. Sinus tachyarrhythmias and the specific bradycardic agents: A marriage made in heaven? *J Cardiovasc Pharmacol Ther.* 2003; 8:89-105.
6. DiFrancesco D, Camm JA. Heart rate lowering by specific and selective I_f current inhibition with ivabradine: A new therapeutic perspective in cardiovascular disease. *Drugs.* 2004; 64:1757-1765.

(Received May 4, 2014; Accepted June 27, 2014)