

Combination chemotherapy with S-1 and docetaxel for cutaneous angiosarcoma resistant to paclitaxel

Ikko Kajihara*, Hisashi Kanemaru, Taiga Miyake, Jun Aoi, Shinichi Masuguchi, Satoshi Fukushima, Masatoshi Jinnin, Hironobu Ihn

Department of Dermatology and Plastic Surgery, Faculty of Life Sciences, Kumamoto University, Kumamoto, Japan.

Summary

The prognosis of cutaneous angiosarcoma is very poor compared with that of other skin malignancies. The main reason for this is the limited regimens of chemotherapy available for angiosarcoma, because it is resistant to most common chemotherapeutic agents. Therefore, there is an urgent need to identify new treatment options. Recently, S-1 and docetaxel therapy was reported to be effective for advanced gastric cancer and metastatic extramammary Paget's disease. Therefore, we treated paclitaxel-resistant angiosarcoma patient with S-1/docetaxel chemotherapy. The progression-free survival was 5.0 months although grade 3 adverse events such as diarrhea and neutropenia developed. Our data need to be confirmed in a large number of patients, but S-1/docetaxel chemotherapy as an additional regimen seems to be an effective treatment option for paclitaxel-resistant angiosarcoma.

Keywords: Angiosarcoma, chemotherapy, paclitaxel, S-1, docetaxel

1. Introduction

Angiosarcoma is a rare sarcoma derived from endothelial cells. The prognosis is poor because the five-year survival rate is generally 12-24% (1). The reported agents with efficacy against angiosarcoma are paclitaxel (PTX) (2,3), docetaxel (DOC) (4,5), gemcitabine (GEM) (6), bevacizumab (7) and sorafenib (8). However, it is difficult to inhibit the disease progressing to advanced angiosarcoma, which is resistant to standard chemotherapy. Therefore, it is necessary to identify new efficacious regimens. In recent years, combination chemotherapy using S-1 and DOC has demonstrated to have curative effects against gastric cancer (9) and metastatic extramammary Paget's disease (10). S-1 and DOC combination therapy for advanced gastric cancer is more effective than DOC monotherapy *in vitro* (11). We speculated that the efficacy of DOC monotherapy as second-line therapy may be inadequate in PTX-resistant cases because

both DOC and PTX are tubulin inhibitors. Thus, we expected an enhanced therapeutic response resulting from the combined use DOC with S-1. We herein report PTX-refractory angiosarcoma patient who received S-1/DOC treatment.

2. Method

S-1/DOC chemotherapy was used as second-line therapy in patient with advanced angiosarcoma resistant to PTX. PTX-resistant was defined as the incidence of disease progression in angiosarcoma patients treated with PTX therapy. The protocol was basically oral S-1 (80 mg/m²/day, day 1- day14) and intravenous DOC (40 mg/m², day 1) every four weeks in reference to a past report (10). The therapeutic efficacy was estimated every one month by examining the clinical symptoms, ultrasound (US) and/or computed tomography (CT) and/or positron-emission tomography (PET) findings. The progression-free survival (PFS) was evaluated from the day when S-1/DOC therapy was started until disease progress. Toxic effects were analyzed using the National Cancer Institute's Common Terminology Criteria version 4.0. When severe adverse events (more than grade 3) were observed, the dose of both S-1 and DOC was reduced by 20%. Institutional review board

*Address correspondence to:

Dr. Ikko Kajihara, Department of Dermatology and Plastic Surgery, Faculty of Life Sciences, Kumamoto University, 1-1-1 Honjo, Kumamoto, Japan.
E-mail: kajiderma@gmail.com

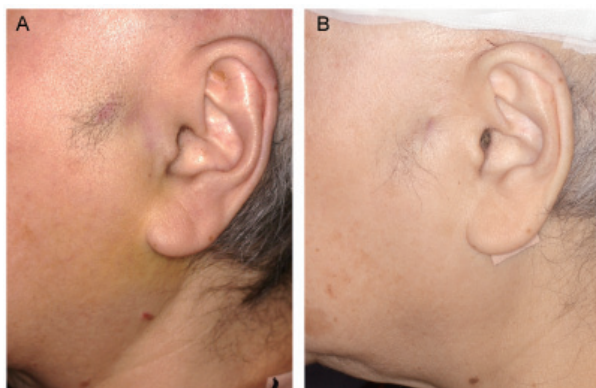


Figure 1. Purpura and purple nodules on the left cheek in case 1. (A) Before S-1 and docetaxel therapy. (B) Two months after the start of this regimen.

approval and written informed consent for this study were obtained according to the Declaration of Helsinki.

3. Case report

A 70-year-old female was diagnosed as having scalp angiosarcoma without lymph node or distant metastasis. The patient received four cycles of tri-weekly PTX therapy (175 mg/m²), surgery (margin of 2 cm), radiation (total of 70 Gy) and eight cycles of tri-weekly PTX therapy as adjuvant chemotherapy. At the end of these treatments, the interval of the PTX regimen was six weeks, in compliance with her wishes, because US and PET indicated no recurrence. However, after four months of this regimen, she developed purpura and purple nodules on her left cheek (Figure 1A). A histopathological examination showed relapsed angiosarcoma. PET showed no metastasis in the lymph nodes or distant organs. We thought that her angiosarcoma cells developed tolerance to PTX. As a second-line treatment, monthly S-1 (120 mg, 80 mg/m²) /DOC (60 mg, 40 mg/m²) therapy was administered. After one cycle, she developed grade 3 diarrhea and neutropenia, so the dose of both agents was reduced by 20%. Two months later, her eruptions had gradually improved (Figure 1B). However, at five months after the initiation S-1/DOC therapy, PET revealed metastasis in the periauricular lymph nodes.

4. Discussion

To our knowledge, this study is the first report of the use of S-1/DOC therapy in patients with PTX-resistant angiosarcoma. We tried this regimen on the basis of the findings of *in vitro* experiments and previous clinical studies. First, both PTX and DOC essentially have the anti-tumor action through blocking tubulin. Second, S-1 has the antineoplastic efficacy through the inhibition of dihydropyrimidine dehydrogenase activity (12). Thirdly, the combination chemotherapy with S-1 and DOC increased anti-cancer effects of treatment compared

with DOC monotherapy in gastric cancer (9,11). Finally, S-1/DOC therapy was reported to be successful against metastatic extramammary Paget's disease (10). Taken together, we expected the synergy effect of S-1/DOC therapy for PTX-resistant angiosarcoma.

Our patient achieved a partial response for five months. Although that of GEM was 5.5 months in 19 taxane-exposed cutaneous angiosarcoma patients (6), that of sorafenib was 1.8 months in superficial angiosarcoma including chemotherapy-naïve patients (8). Our study may suggest that S-1/docetaxel therapy may at least stabilize the disease.

With regard to severe toxicity (more than grade 3), there were severe adverse events observed in our case, including neutropenia and diarrhea. Other adverse events (all were only grade 1) included watering eyes and malaise. We speculated that the reason for severe toxicity may have been the functional decline of the bone marrow due to the previous PTX therapy. It will be necessary to adjust the initial dose for inextirpable angiosarcoma in the future.

Taken together, the present findings indicate that S-1/DOC therapy may be an alternative option for patients with PTX-resistant angiosarcoma because there were limited regimens for advanced angiosarcoma. However, further studies of this treatment in a large series of patients are needed to verify its efficacy and safety.

Acknowledgements

This study was supported in part by a grant for scientific research from the Japanese Ministry of Education, Science, Sports and Culture.

References

- Vogt T, Brockmeyer N, Kutzner H, Schofer H. Brief s1 guidelines-cutaneous angiosarcoma and kaposi sarcoma. *J Dtsch Dermatol Ges.* 2013; 11:(Suppl 3):2-9, 2-10.
- Fata F, O'Reilly E, Ilson D, Pfister D, Leffel D, Kelsen DP, Schwartz GK, Casper ES. Paclitaxel in the treatment of patients with angiosarcoma of the scalp or face. *Cancer.* 1999; 86:2034-2037.
- Penel N, Bui BN, Bay JO, *et al.* Phase II trial of weekly paclitaxel for unresectable angiosarcoma: The angiotax study. *J Clin Oncol.* 2008; 26:5269-5274.
- Nagano T, Yamada Y, Ikeda T, Kanki H, Kamo T, Nishigori C. Docetaxel: A therapeutic option in the treatment of cutaneous angiosarcoma: Report of 9 patients. *Cancer.* 2007; 110:648-651.
- Fujisawa Y, Yoshino K, Kadono T, Miyagawa T, Nakamura Y, Fujimoto M. Chemoradiotherapy with taxane was superior to conventional surgery and radiotherapy in the management of cutaneous angiosarcoma: Multi-center, retrospective study. *Br J Dermatol.* 2014; 171:1493-1500.
- Stacchiotti S, Palassini E, Sanfilippo R, Vincenzi B, Arena MG, Boichicchio AM, De Rosa P, Nuzzo A, Turano S, Morosi C, Dei Tos AP, Pilotti S, Casali PG. Gemcitabine in advanced angiosarcoma: A retrospective case series

- analysis from the italian rare cancer network. *Ann Oncol.* 2012; 23:501-508.
7. Agulnik M, Yarber JL, Okuno SH, von Mehren M, Jovanovic BD, Brockstein BE, Evens AM, Benjamin RS. An open-label, multicenter, phase II study of bevacizumab for the treatment of angiosarcoma and epithelioid hemangioendotheliomas. *Ann Oncol.* 2013; 24:257-263.
 8. Ray-Coquard I, Italiano A, Bompas E, *et al.* Sorafenib for patients with advanced angiosarcoma: A phase II trial from the french sarcoma group (GSF/GETO). *Oncologist.* 2012; 17:260-266.
 9. Yoshida K, Ninomiya M, Takakura N, Hirabayashi N, Takiyama W, Sato Y, Todo S, Terashima M, Gotoh M, Sakamoto J, Nishiyama M. Phase II study of docetaxel and S-1 combination therapy for advanced or recurrent gastric cancer. *Clin Cancer Res.* 2006; 12:3402-3407.
 10. Matsushita S, Yonekura K, Mera K, Kawai K, Kanekura T. Successful treatment of metastatic extramammary paget's disease with s-1 and docetaxel combination chemotherapy. *J Dermatol.* 2011; 38:996-998.
 11. Wada Y, Yoshida K, Suzuki T, Mizuiri H, Konishi K, Ukon K, Tanabe K, Sakata Y, Fukushima M. Synergistic effects of docetaxel and s-1 by modulating the expression of metabolic enzymes of 5-fluorouracil in human gastric cancer cell lines. *Int J Cancer.* 2006; 119:783-791.
 12. Tatsumi K, Fukushima M, Shirasaka T, Fujii S. Inhibitory effects of pyrimidine, barbituric acid and pyridine derivatives on 5-fluorouracil degradation in rat liver extracts. *Jpn J Cancer Res.* 1987; 78:748-755.

(Received January 28, 2015; Revised February 10, 2015; Accepted February 11, 2015)